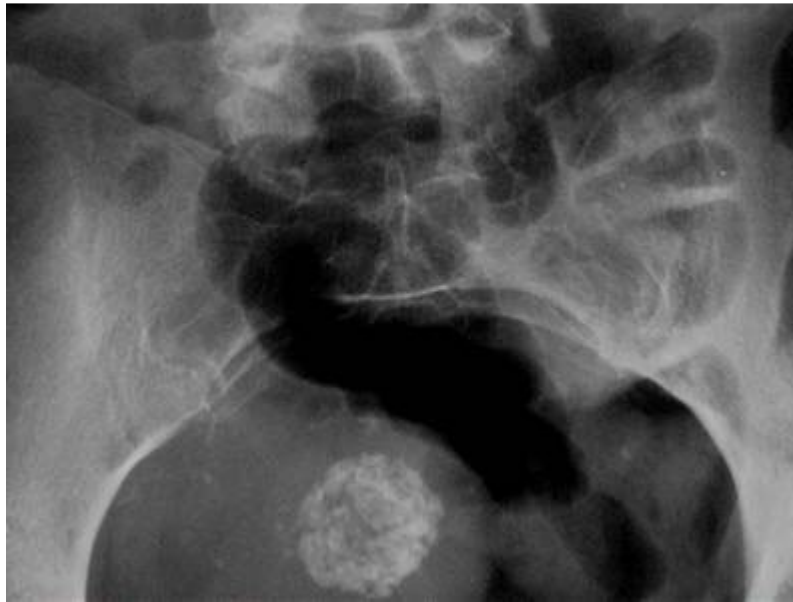


Calcified Uterine Fibromas



Calcified uterine fibromas are common incidental findings in the pelvis of postmenopausal women. Invariably, they are asymptomatic. The radiographic appearance is distinct, with a cluster of small calcifications described as “mulberry-like” in appearance. They can be singular or multiple and range from small to quite large. Typically they do not require any additional follow-up. However, I recommend informing the patient’s Ob/Gyn or primary medical provider that it has been identified.