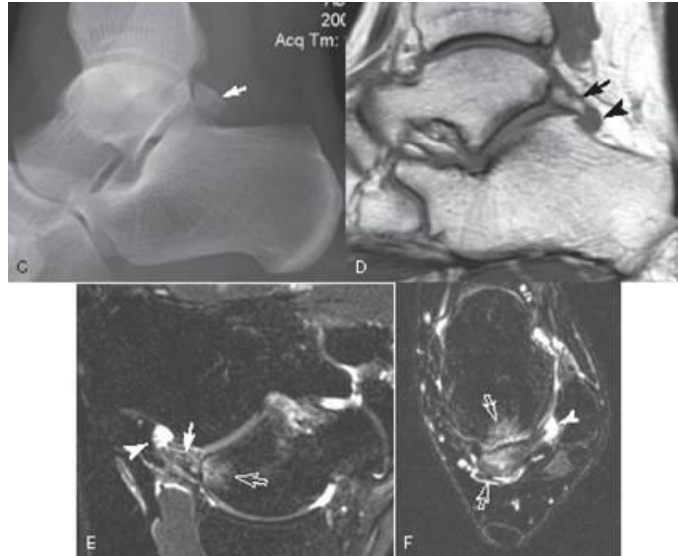


Os Trigonum



The os trigonum is a somewhat common normal variant seen in the ankle. It presents as a well defined somewhat triangular ossicle posterior to the talus. The smooth well defined cortical edges and its location differentiate it from a fracture. In most instances it is an incidental finding with no clinical significance. On rare instances it can be a cause of posterior ankle impingement resulting in posterior ankle pain especially in plantar flexion. The symptomatic ones can ONLY be identified with MR which will show bone marrow edema in the os and adjacent talus (arrows) and often a small ganglion cyst (open arrow).

Treatment is usually conservative.