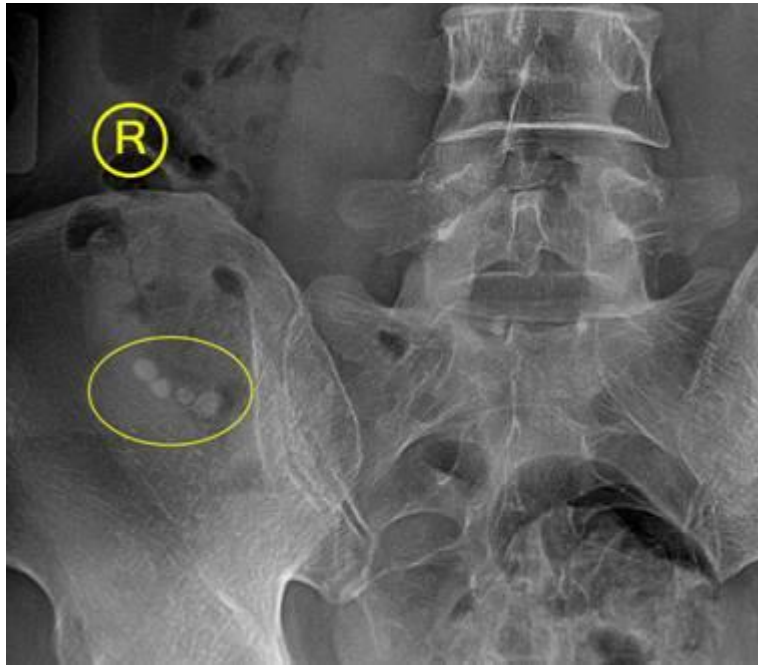


# Stones



Stones in the appendix, fecoliths or appendicoliths, rarely calcify. However, when they do calcify, they are radiographically distinct. They are usually seen as multiple small well defined homogenous calcifications in the right lower quadrant of the abdomen. When associated with acute pain in the area, it is indicative of appendicitis. However, they are usually seen as incidental findings without localized right lower quadrant pain. They can result in appendicitis, so patients should be made aware of the signs of appendicitis so they can seek immediate care in the event of an attack.