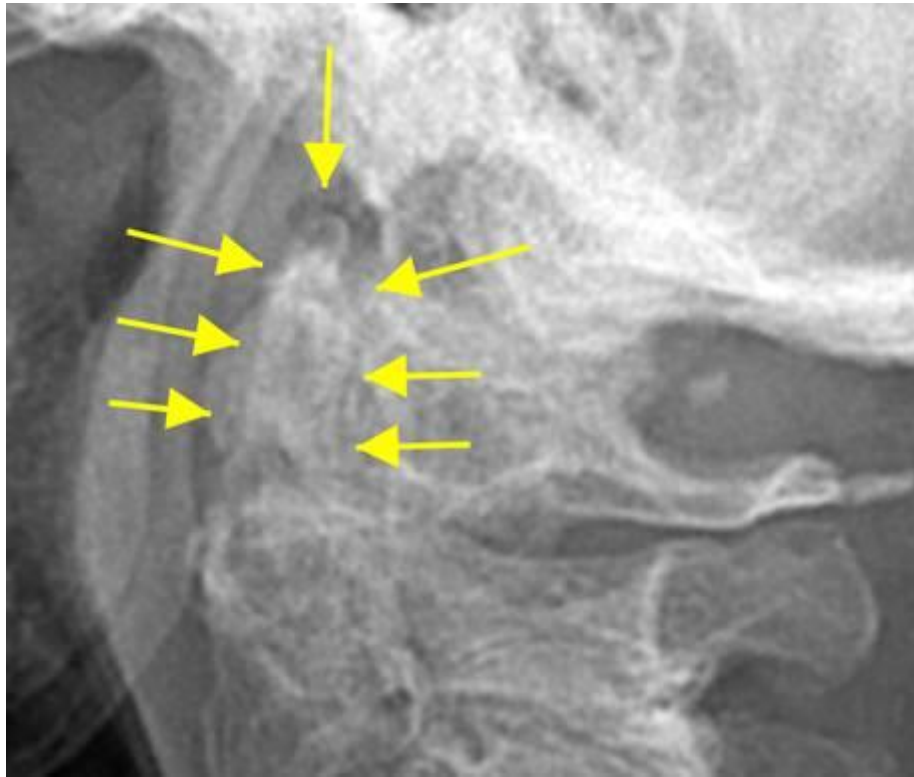


Whittled Odontoid



The whittled odontoid appearance is an important and dangerous finding seen in inflammatory diseases that affect the spine, such as in this recent chiropractic patient who had never properly been diagnosed with RA. The erosions come from pannus in the ADI, inflammation of the bursa between the dens and transverse ligament, as well as inflammation of the alar ligament. Patients often do not have symptoms until triggered by a trauma as was the case here. It is an absolute contraindication to adjusting. The patient should be put in a hard collar, assessed with MRI, and referred to a neurosurgeon.