

Back To Chiropractic CE Seminars

CERVICAL SPINE: X-RAY Case Presentations ~ 5 Hours


Welcome to Back To Chiropractic Online CE exams:

This course counts toward your California Board of Chiropractic Examiners CE. (also accepted in other states, check our website or with your Chiropractic State Board)

The California Board requires that you complete all of your CE hours BEFORE the end of your Birthday month. We recommend that you send your chiropractic license renewal form and fee in early to avoid any issues.

COPYRIGHT WARNING

The copyright law of the United States (Title 17, United States Code) governs the making of photocopies or other reproductions of copyrighted material. Under certain conditions specified in the law, libraries and archives are authorized to furnish a photocopy or other reproduction. One of these specified conditions is that the photocopy or reproduction is not to be "used for any purpose other than private study, scholarship, or research." If a user makes a request for, or later uses, a photocopy or reproduction for purposes in excess of "fair use," that user may be liable for copyright infringement. This site reserves the right to refuse to accept a copying order if, in its judgment, fulfillment of the order would involve violation of the copyright law.



Exam Process: Read all instructions before starting!

- 1. You must register/pay first. If you haven't, please return to: backtochiropractic.net**
- 2. Open a new window or a new internet tab & drag it so it's side-by-side next to this page.**
- 3. On the new window or new tab you just opened, go to: backtochiropractic.net website.**
- 4. Go directly to the Online section. DON'T register again.**
- 5. Click on the Exam for the course you want to take. No passwords needed.**
- 6. Follow the Exam instructions.**
- 7. Upon passing exam, you'll be able to immediately download your certificate, and it'll also be emailed to you. If you don't pass, you must repeat the exam.**

**Please retain the certificate for 5 years. DON'T send it to the state board.
If you get audited and lose your records, I'll have a copy.**

I'm always a phone call away... 707.972.0047 or email: marcusstrutzdc@gmail.com

**Marcus Strutz, DC
Back To Chiropractic CE Seminars**

CERVICAL SPINE: X-RAY

Case Presentations

Jennifer Pedley, MS, DC, CCSP, DACBR
Chiropractic Radiologist

www.jprad.com



Outline

- Radiology positioning
- Evaluating your xrays
 - ABCs
- Case studies of the cervical spine
 - Topics of congenital anomalies, degenerative changes & trauma.

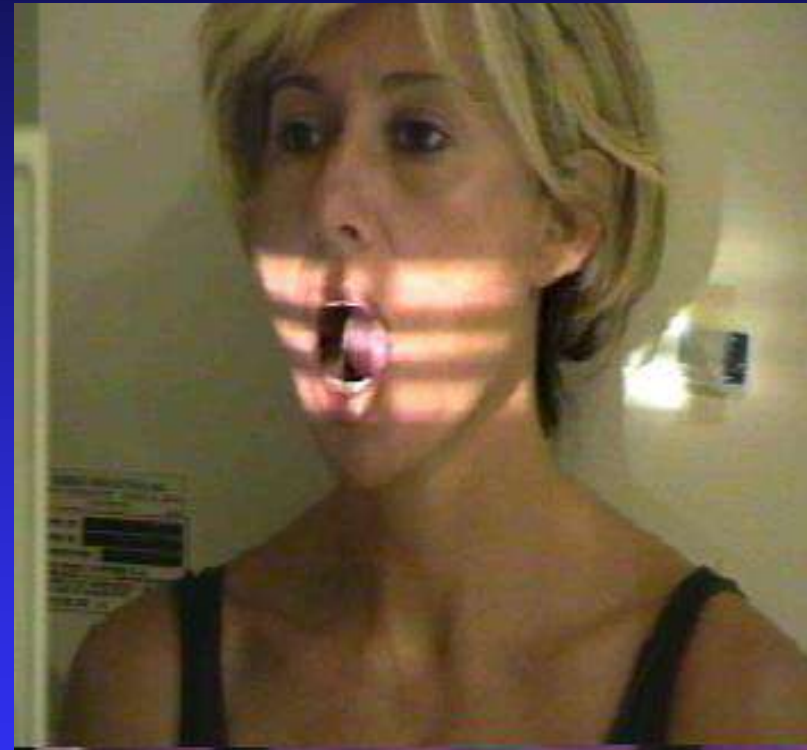Cervical Spine Views

3 Views-

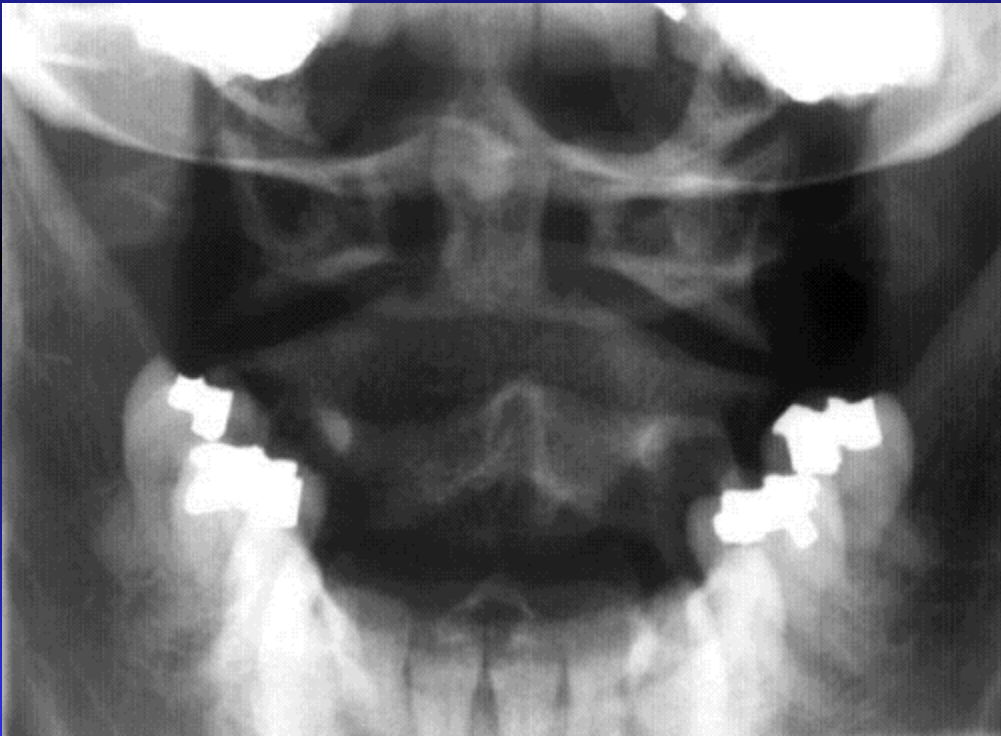
- APOM, AP lower cervical, and neutral lateral performed first; standard views
- Followed by extended and flexed lateral views>>> evaluate for ligamentous laxity and/or instability
 - Oblique views are helpful in evaluating the intervertebral foramina

APOM

- **FFD** 40"
- **CR** uvula; 5 degree cephalad tube tilt
- **Collimate** 5x5



AP OPEN MOUTH

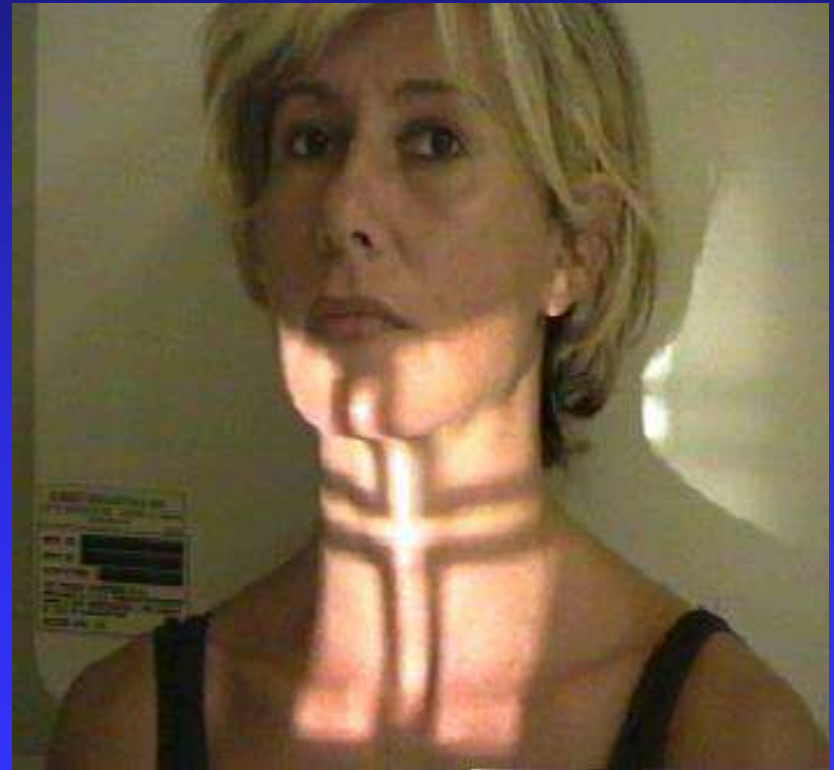

Structures Visualized:

- Dens
- C1 lateral masses
- Occipital Condyles
- C2 body
- C2 SP

AP Lower Cervical

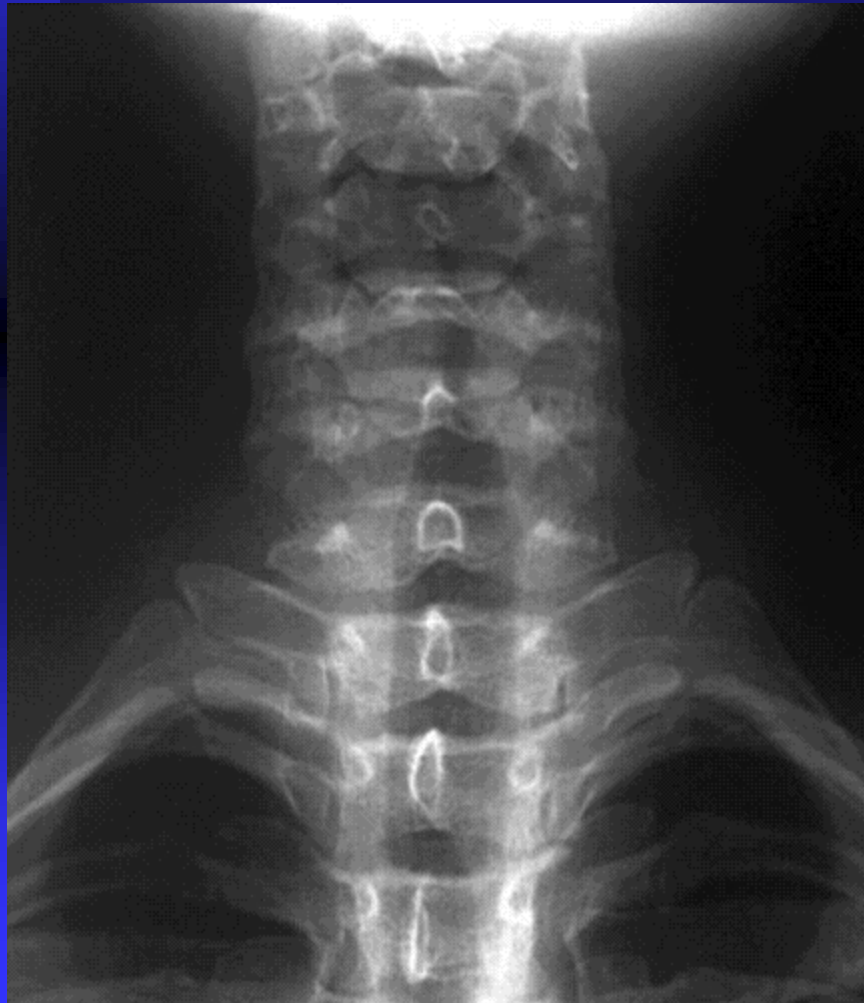
- **FFD** 40-3''
- **Tube Tilt** 15° cephalad
- **CR** C3/4
(thyroid cartilage)
- **Collimate** 7x10



Tube Tilt Rule

- For every 5 degrees of tube tilt, move xray tube one inch closer to the patient
- 15 degree tube tilt=
move tube closer by 3 inches (40 inches to 37 inches)

AP LOWER CERVICAL



Structures Visualized

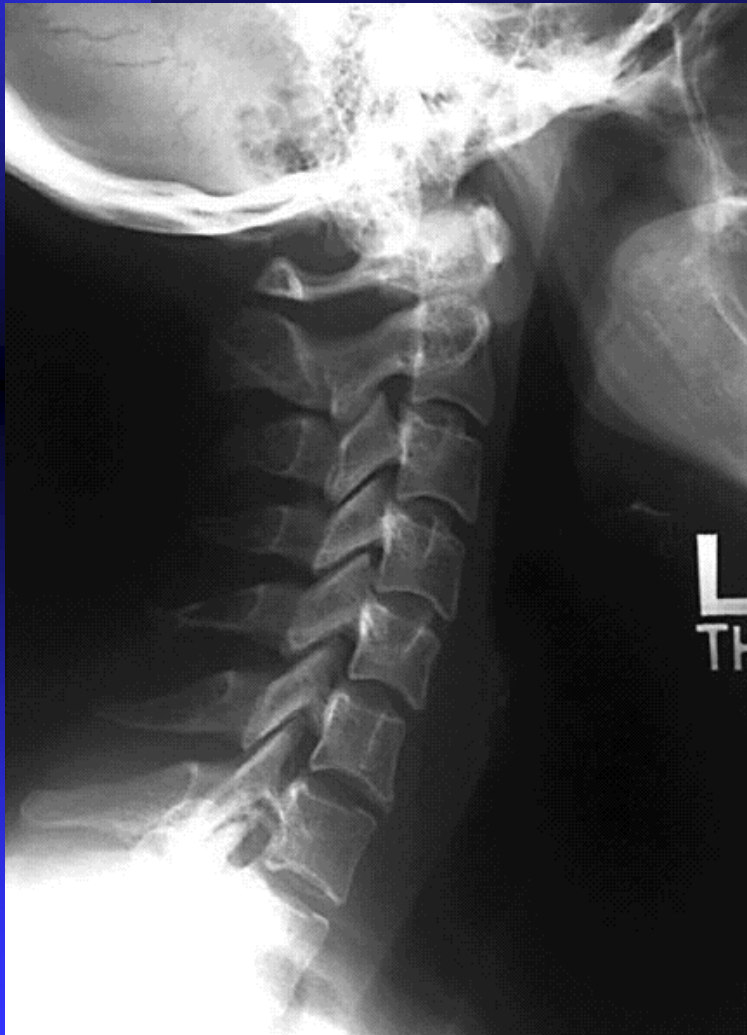- Vertebral Bodies
- TP's
- SP's
- Upper Ribs
- Upper Lung Fields
- Uncinate Processes
- Tracheal Air Shadow

NEUTRAL LATERAL

- **FFD** 72"
- **CR** C3
- **Collimate** 7X10



LATERAL CERVICAL

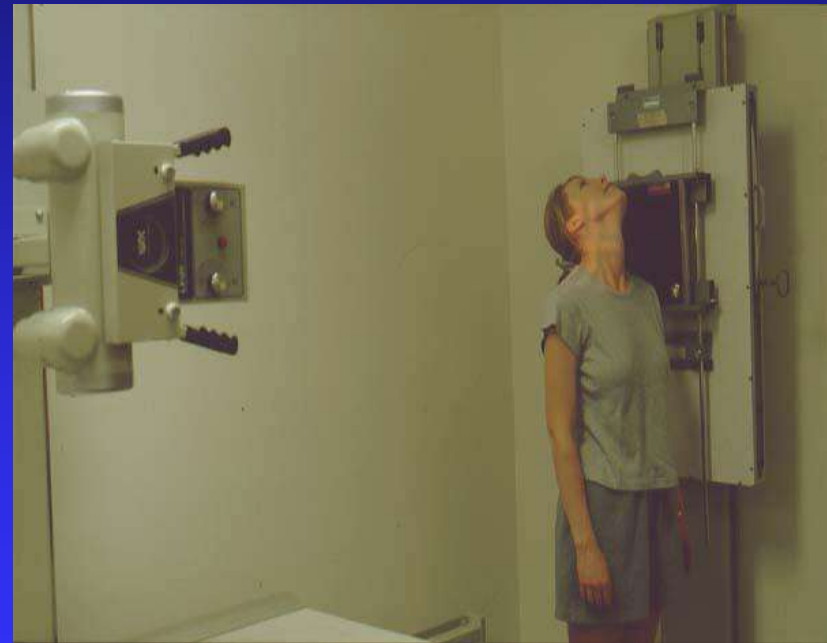

Structures Visualized

- Vertebral bodies C2-T1
- Disc Spaces
- ADI
- SP's, Lamina, Pedicles,
- Articular Pillars and Facets
- Tracheal Air Shadow
- George's Line & Spino-laminar line
- Sella Turcica
- C1 Arches

LATERAL EXTENDED

- **FFD** 72"
- **CR** C3
- **Collimate** 8x10
- May need to be landscape in patients with greater range of motion



LATERAL FLEXED

- **FFD** 72"
- **CR** C3
- **Collimate** 8x10
- May need to be landscape in patients with great range of motion



Posterior vs. Anterior Obliques

Posterior

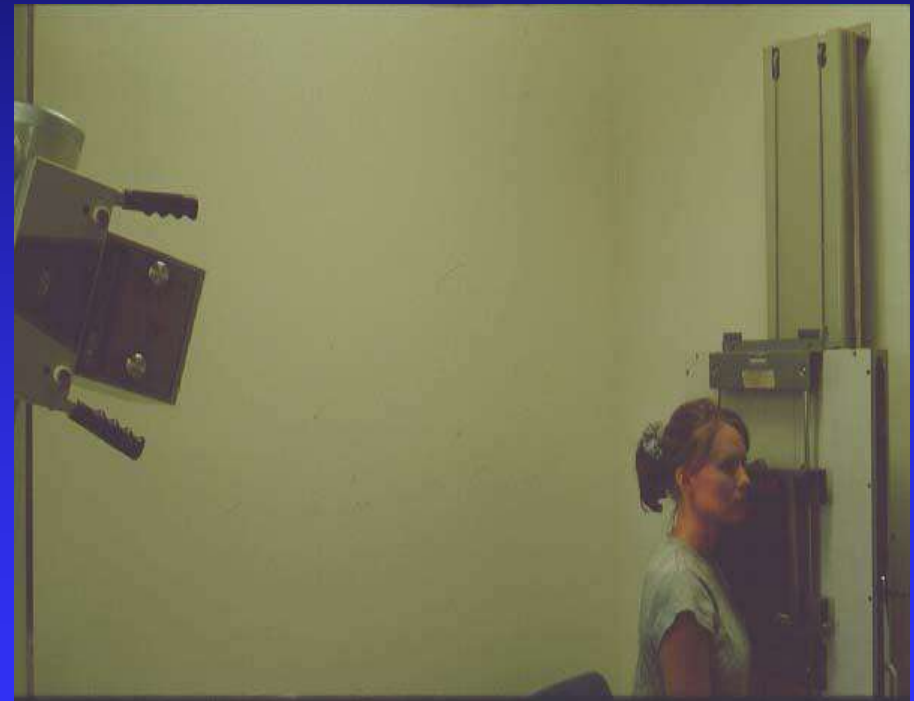- Visualize the opposite IVF's
- Example: Left posterior oblique radiograph, visualizes the right IVF.

Anterior

- Visualize the same side IVF's
- Example: Right anterior oblique radiograph, visualizes the right IVF.

LEFT ANTERIOR OBLIQUE

- FFD 72"
- CR C3
- Tube tilt 15 °
caudad**
- Collimate 7-8x10

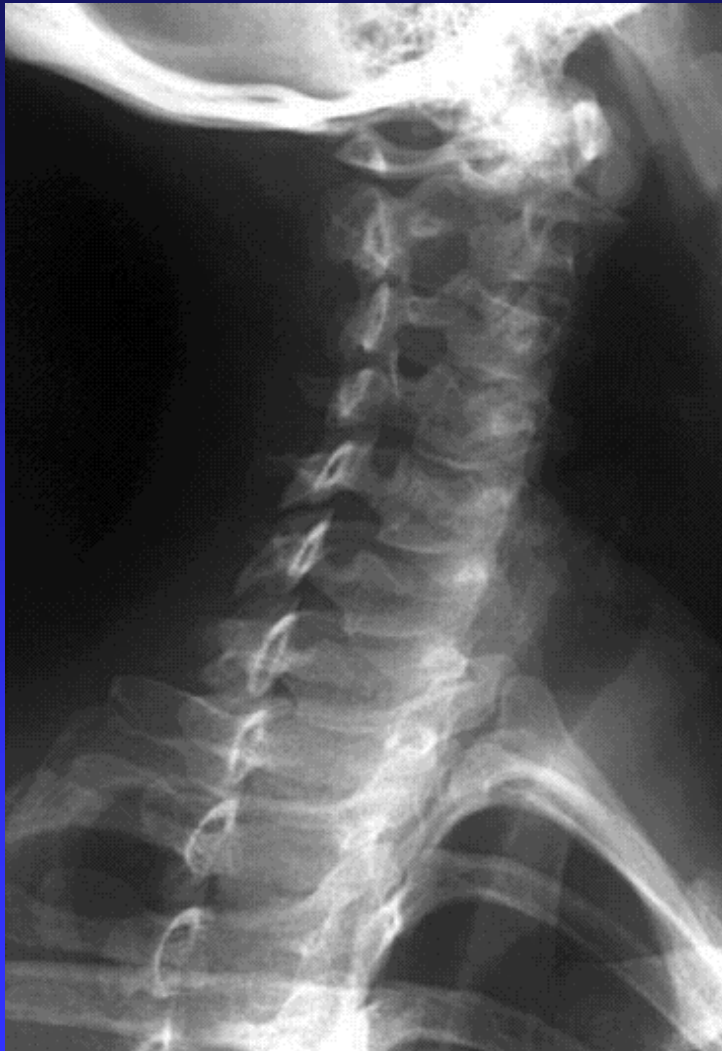

LEFT POSTERIOR OBLIQUE

- **FFD** 72-3''
- **CR** C3
- **Tube tilt** 15 °
cephalad***
- **Collimate** 7-8x10



CERVICAL OBLIQUE

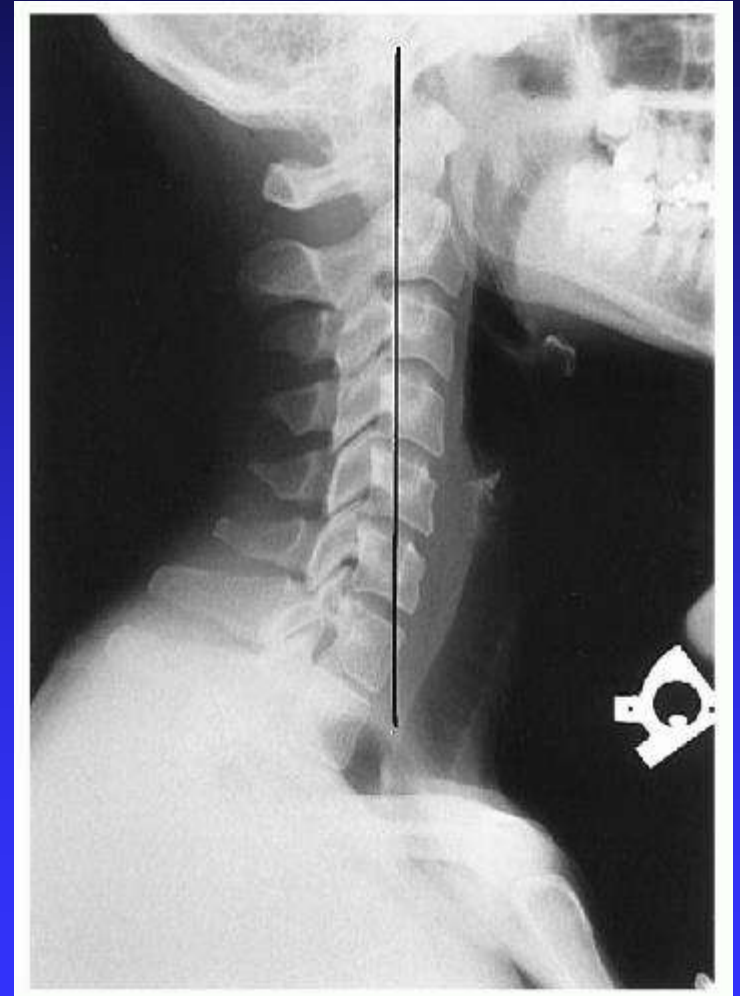

Structures Visualized

- IVF's
- Vertebral Bodies
- C1 arches
- Ribs
- SP's
- Facets

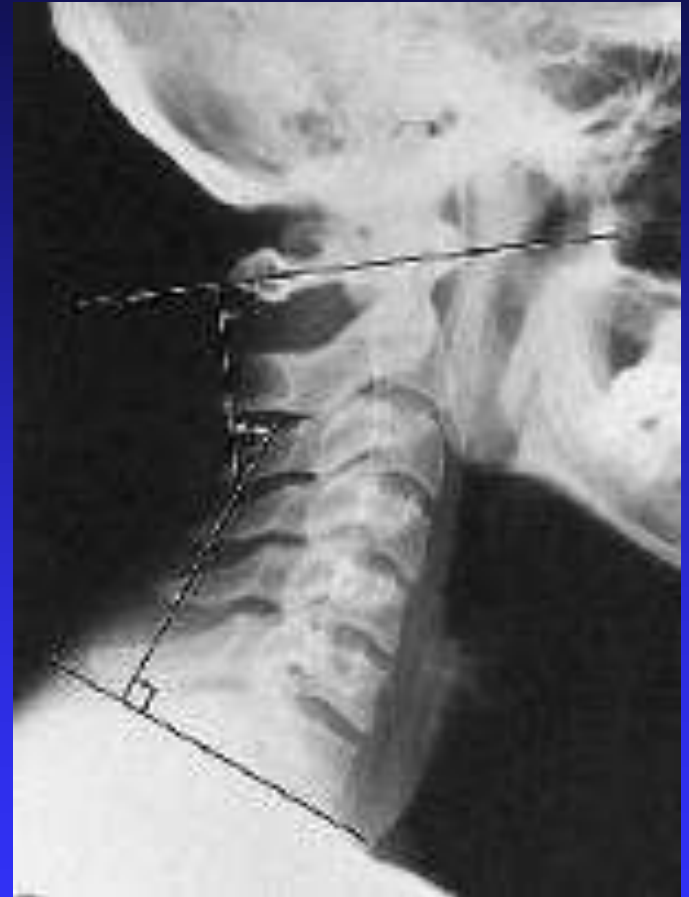Evaluation

- Cervical Gravity Line: Vertical line through apex of odontoid, should intersect C7



Evaluation

- Cervical Lordosis
Angle: Normal 35-45 degree
 - This case, anterior shift in weightbearing

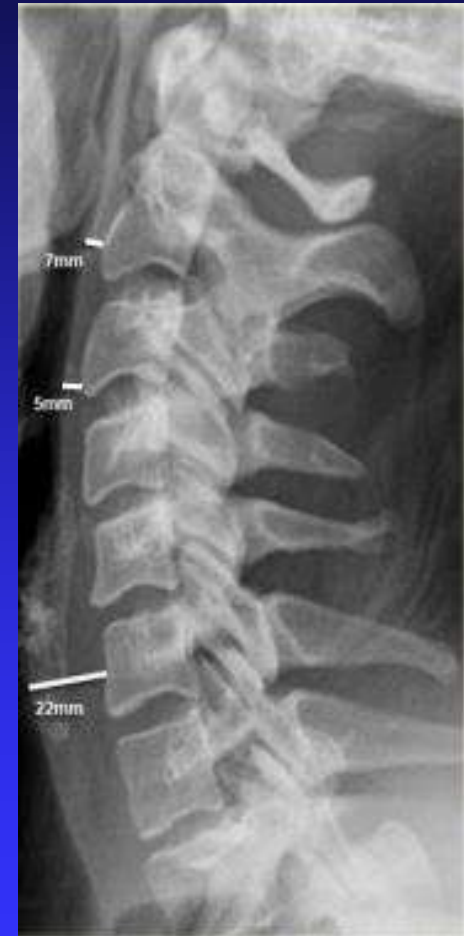

Radiographic Signs of Instability

- Vertebral body displacement $>3-3.5\text{mm}$
- Greater than 11 degree angulation
- Widened interlaminar & interspinous space
- Widened facet joints
- Widened interpediculate distance (AP view)
- Atlanto-dental interspace $>3\text{mm}$ adults; $>5\text{mm}$ in children

These findings indicate skeletal, ligamentous and articular disruption.

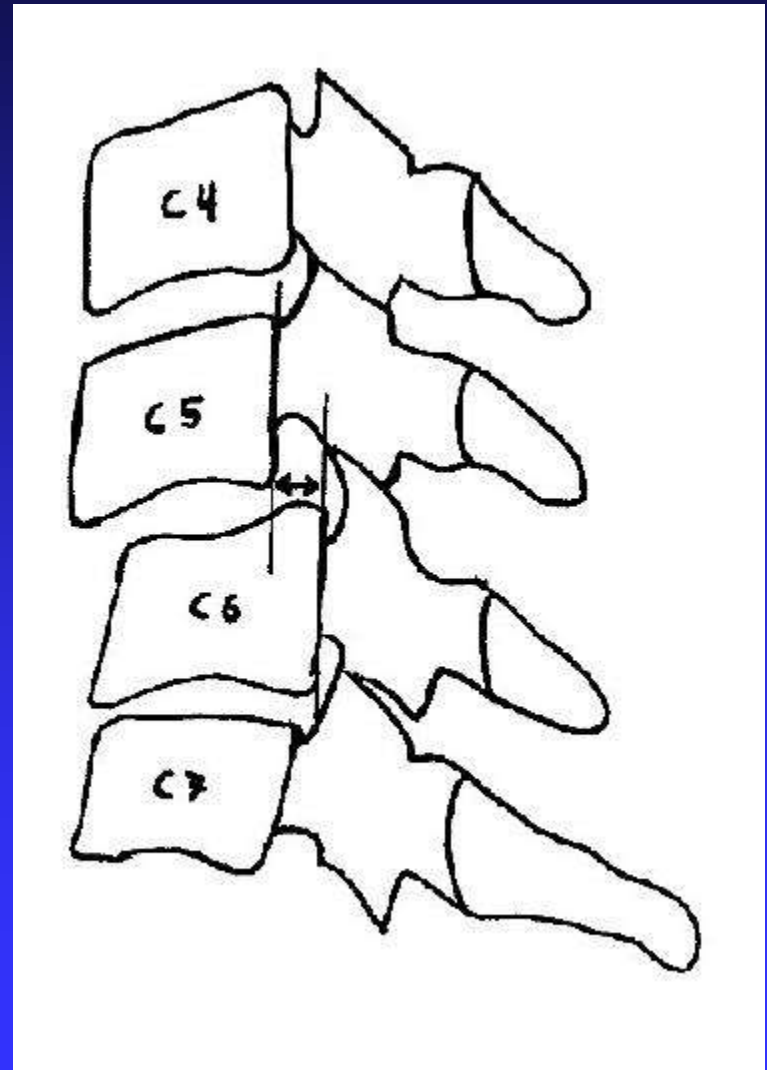
AMA Guides, 5th ed.; Resnick D. Diagnosis of Bone and Joint Disorders, 4th ed. 2002; 2936.



Measuring Intersegmental Translation

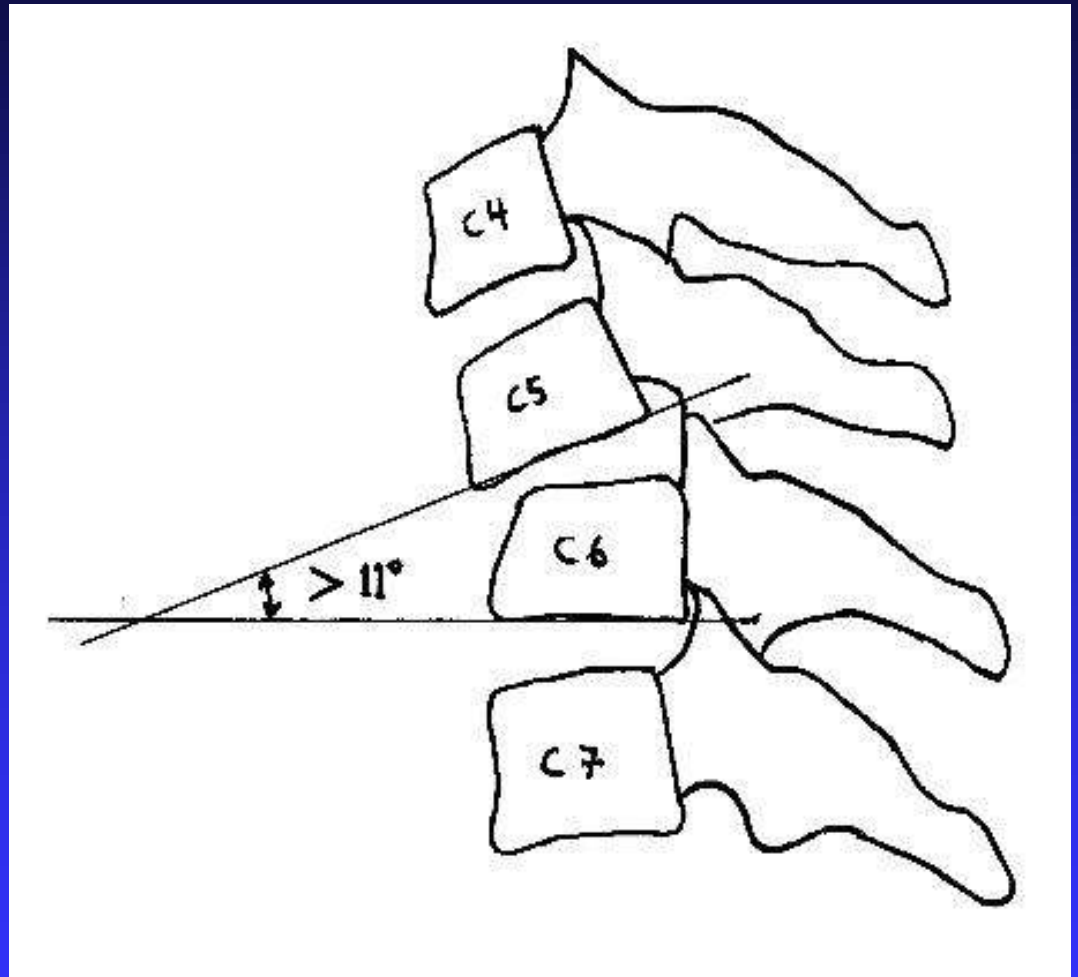
Greater than 3-3.5 mm
of vertebral body
displacement=
ligamentous instability

Need to compare
flexed and extended to
the neutral lateral xray.



Measuring Angulation

- Lines drawn on the Inferior endplates.
- Greater 11 degrees

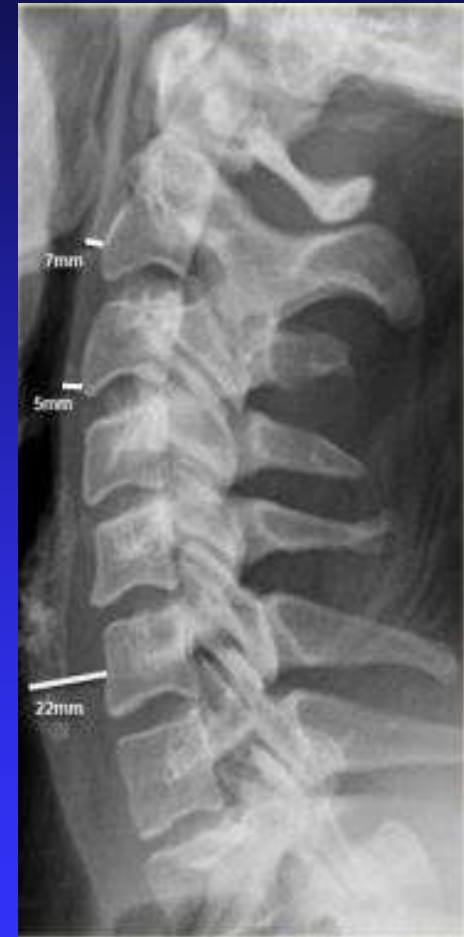

Radiographic Signs of Instability

- Vertebral body displacement $>3-3.5\text{mm}$ (ligamentous instability)
- Greater than 11 degree angulation (ligamentous laxity)
- Widened interlaminar & interspinous space
- Widened facet joints
- Widened interpediculate distance (AP view)
- Atlanto-dental interspace $>3\text{mm}$ adults; $>5\text{mm}$ in children

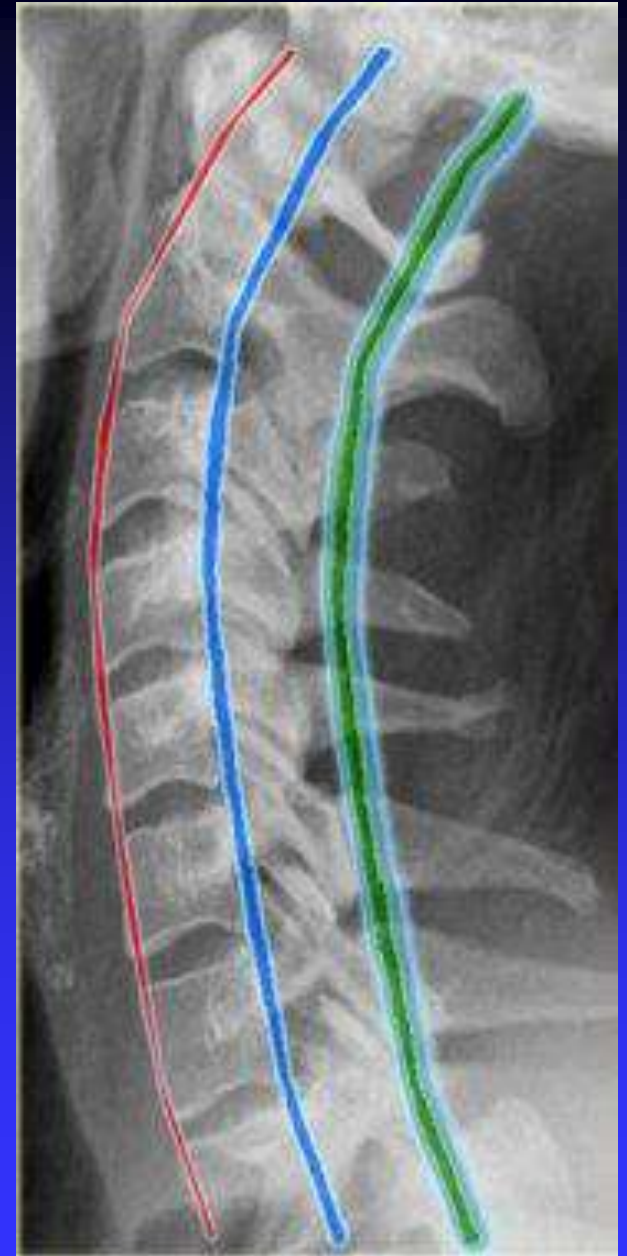
These findings indicate skeletal, ligamentous and articular disruption.

AMA Guides, 5th ed.; Resnick D. Diagnosis of Bone and Joint Disorders, 4th ed. 2002; 2936.



Lines of Interest

- Line should be drawn in a smooth arc. If not, then it requires further evaluation of the region
- Spinolaminar line (green)
- Posterior cervical line (blue)
- Anterior cervical line (anterior)



Other Evaluation Tips

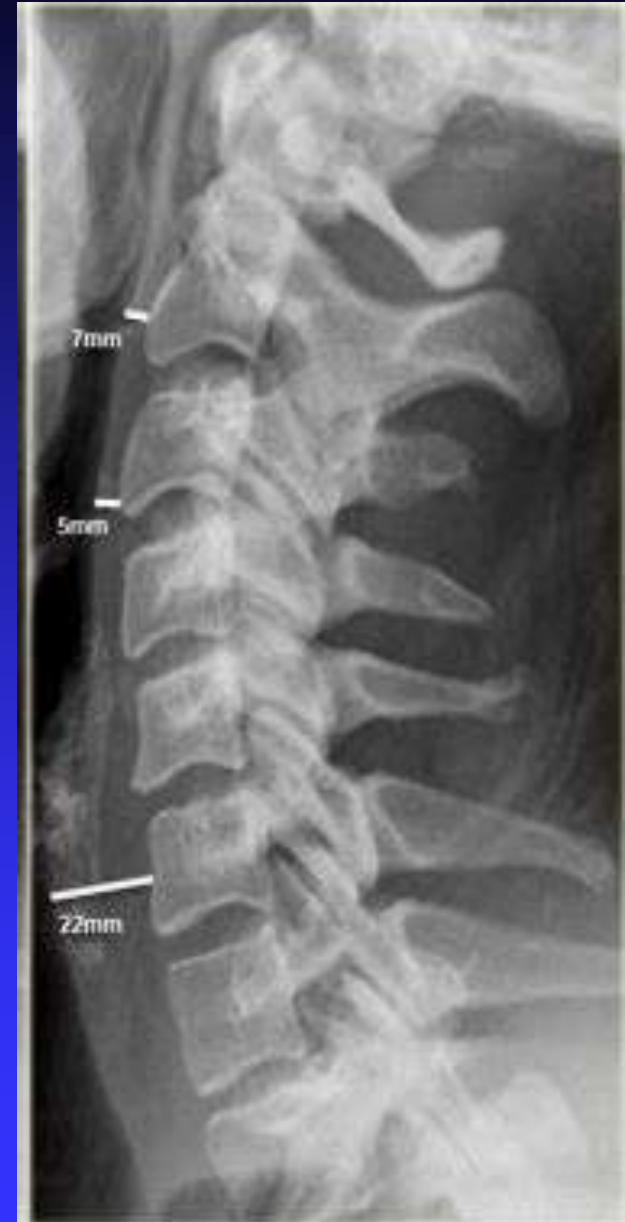- Spinous processes should be equidistant
 - If widening or increased distance, indicator of interspinous ligament injury/disruption.
- Facet joints- no gapping or perched facet joints.

More Evaluation

- ADI-atlantodental interspace
- V-shaped is normal
- Indicator of ligamentous instability (Transverse Ligament) with widening of the ADI on the Neutral lateral, or on the Flexed lateral, or on the Extended lateral.
 - Greater than 3mm in children & greater than 5mm in adults

Lateral cervical spine

- Evaluate the anterior and posterior soft tissues
- Prevertebral (anterior) soft tissues:
 - Retropharyngeal:
>7.0-mm
 - Retrotracheal:
>22.0-mm



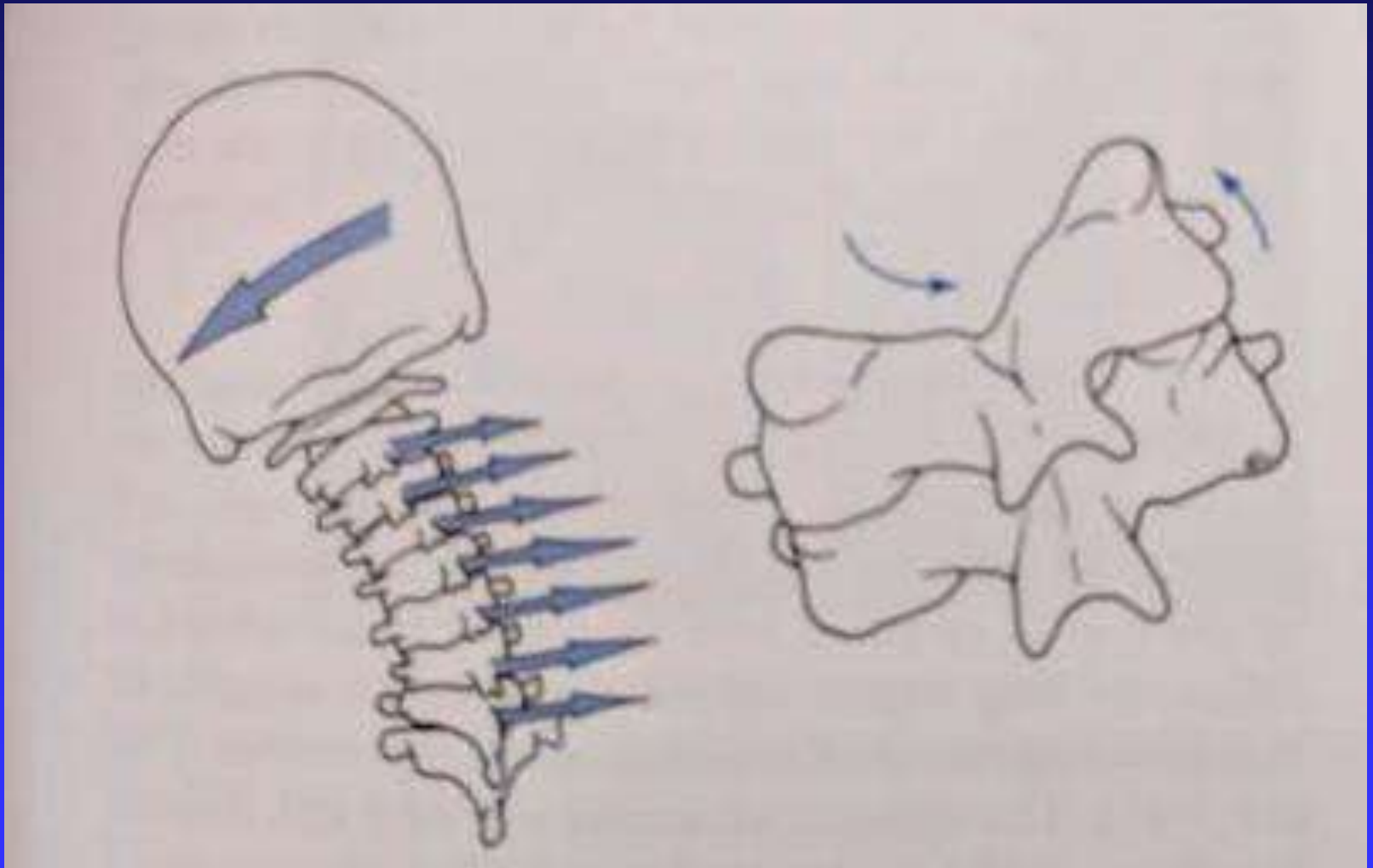
Prevertebral Soft Tissues

- Why do we need to look at them?
 - Widening of the soft tissue and/or increased density= Differential diagnosis is edema due to trauma, infection, or a mass/tumor.

Evaluation

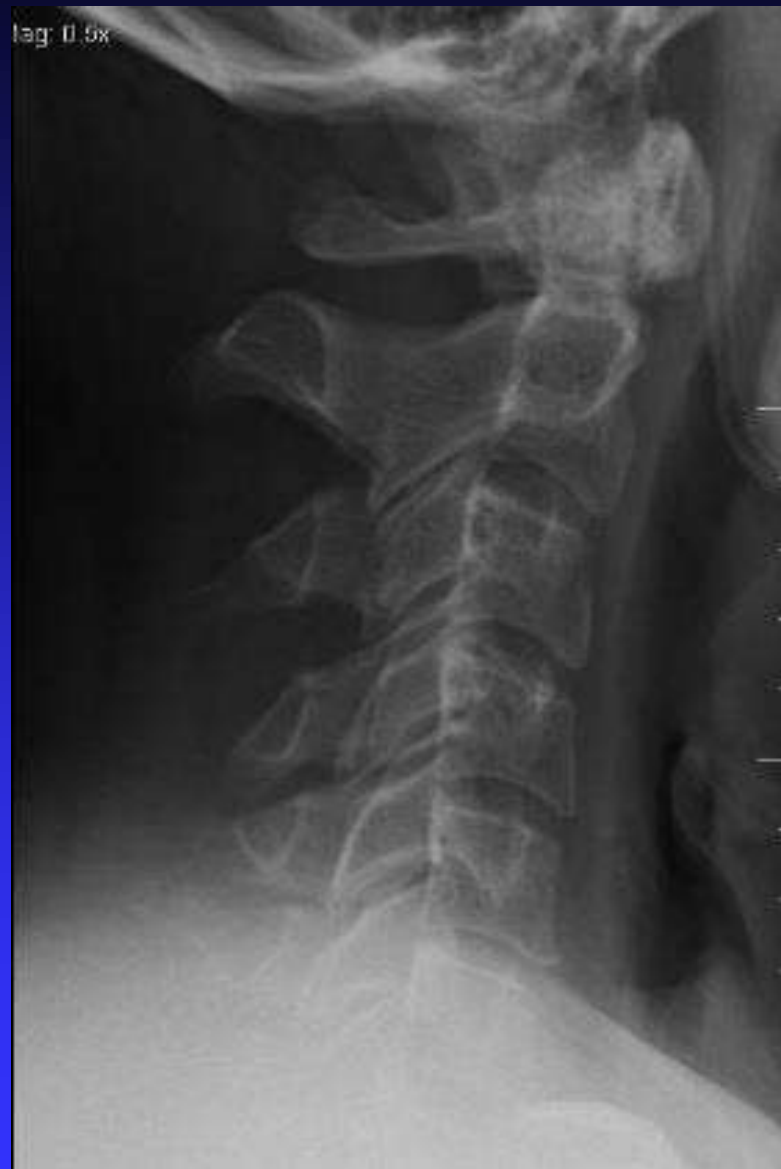- Normal coupling pattern with right and left lateral bending, ipsilateral rotation (spinous process deviates to the opposite side of lateral flexion).
 - Right lateral flexion= right vertebral body rotation, spinous process deviates to the left.
 - Left lateral flexion= left vertebral body rotation, spinous process deviates to the right.
- Upper thoracic spine is same.

Normal Coupling



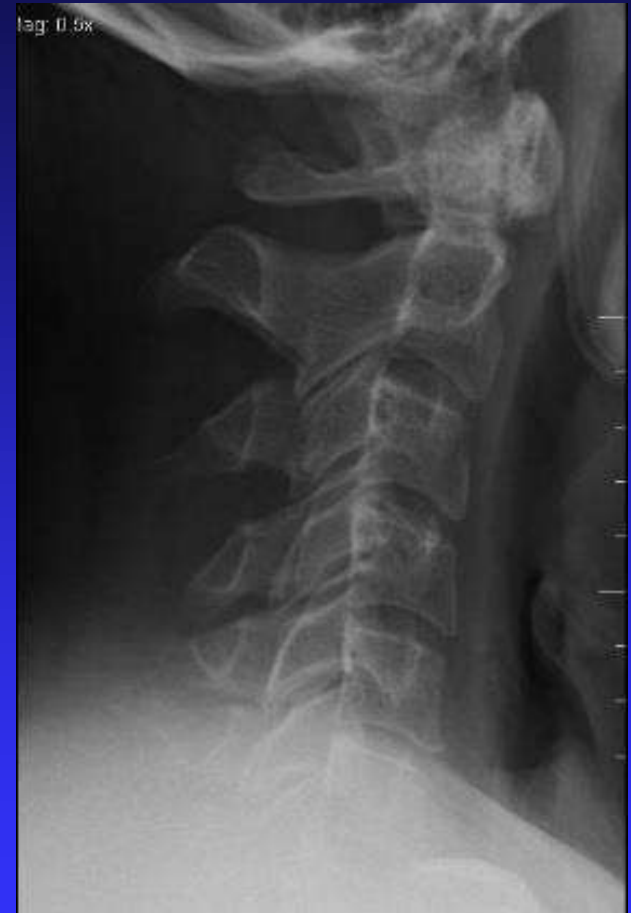Case Study Approach

Case



Diagnosis

- Straightening and reversal of the cervical lordosis- flexion malposition of C2
- Multilevel degenerative disc disease & facet arthrosis
- Congenital cleft of C1 with hypertrophic, sclerotic anterior tubercle



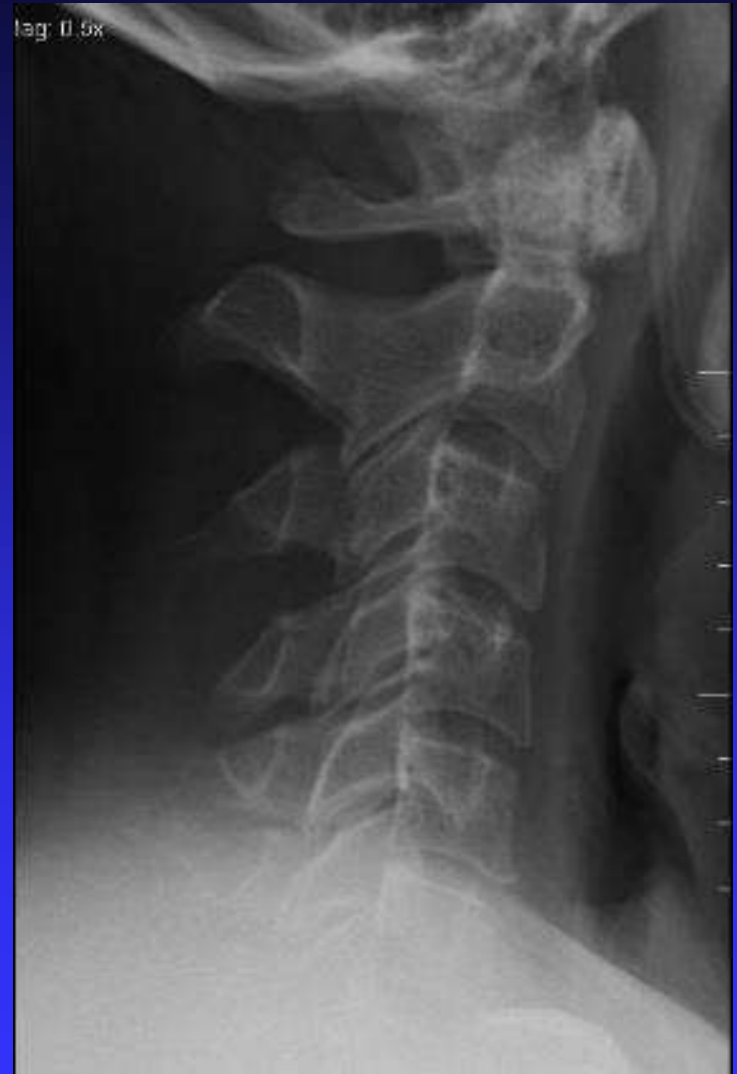Congenital Cleft

Aka synostosis, spondyloschisis,
SBO

- Posterior neural arch of C1 fuses by 3-4 yoa (anterior arch fuses by 7 yoa)

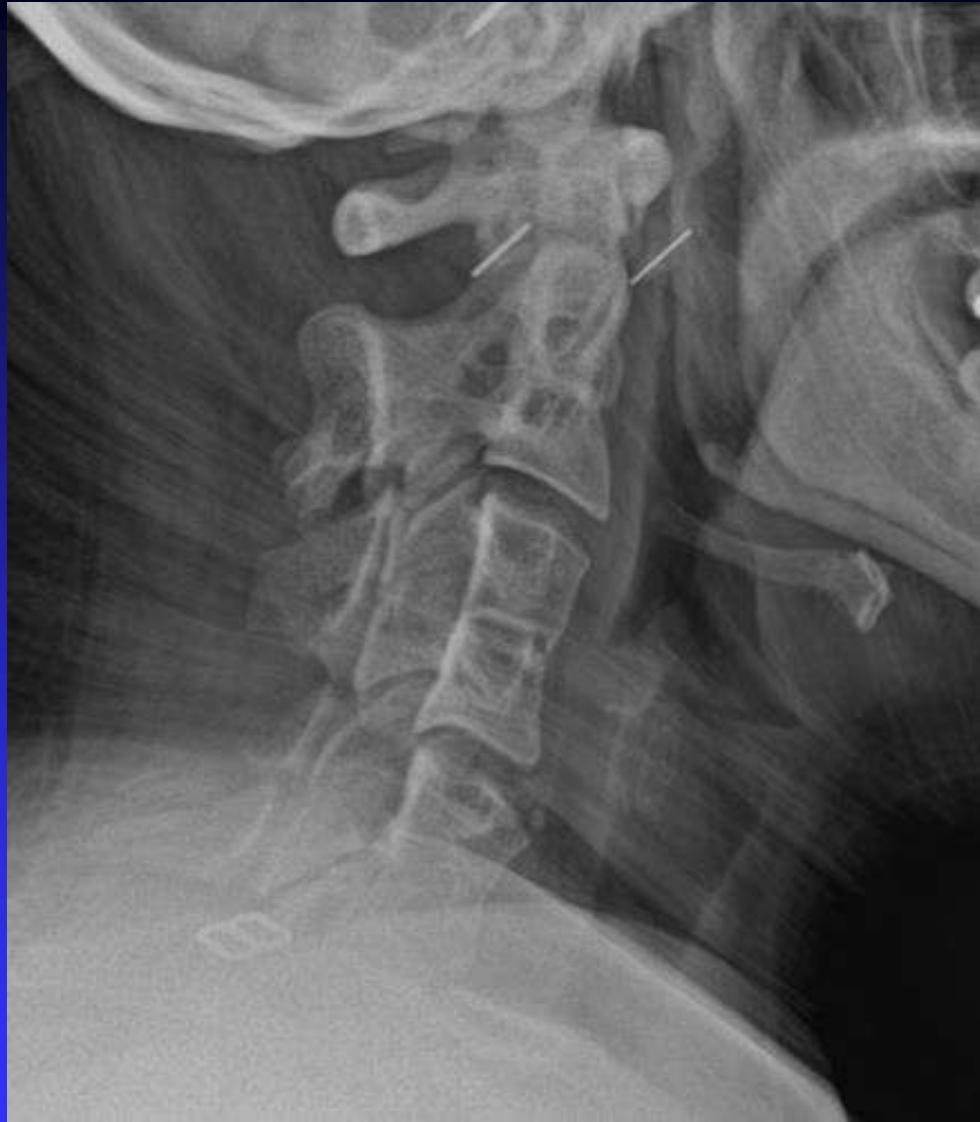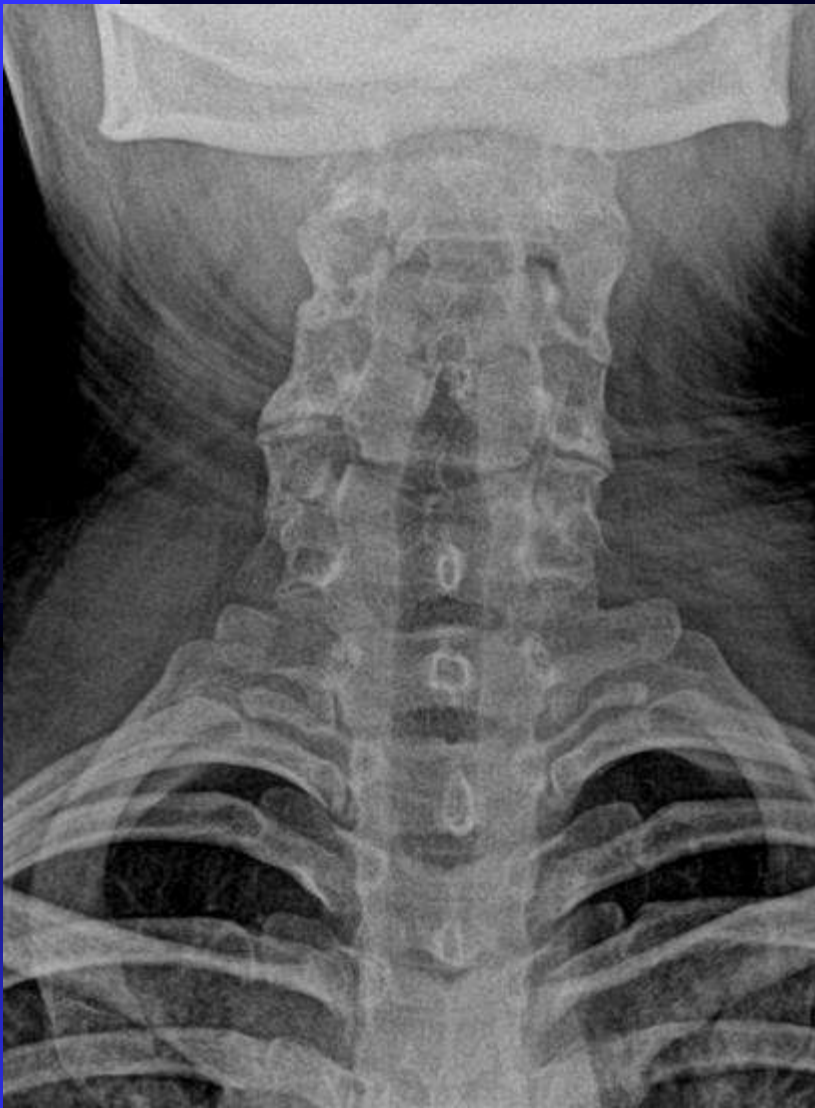Secondary Findings:

- Hypoplastic posterior arch
- Hypertrophy of the anterior tubercle
- **Stable**



Case

- Neck pain following motor vehicle accident.



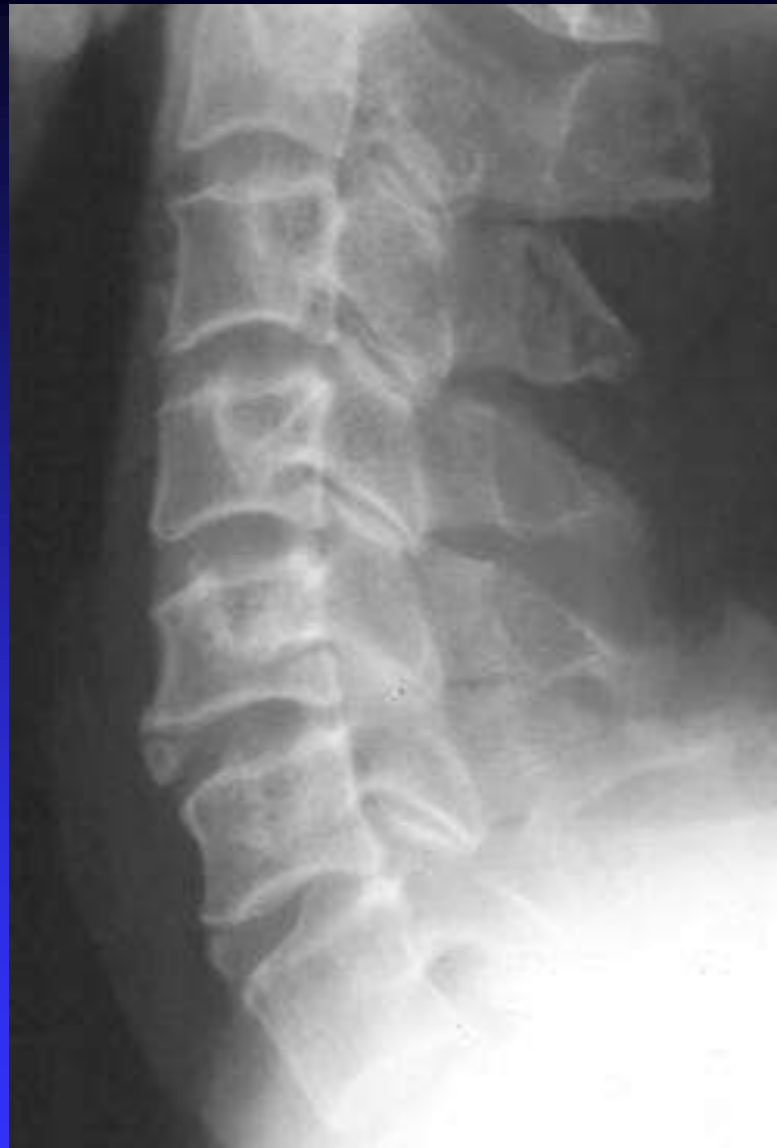Findings/Diagnosis

- Hypolordosis of cervical spine with anterior shift in weightbearing
- Cervical spine tilts to the left.
- Congenital block vertebrae at C2-C3, C4-C5 & C6-C7.
 - Need xrays to evaluate for contraindication or indication for treatment.

Case

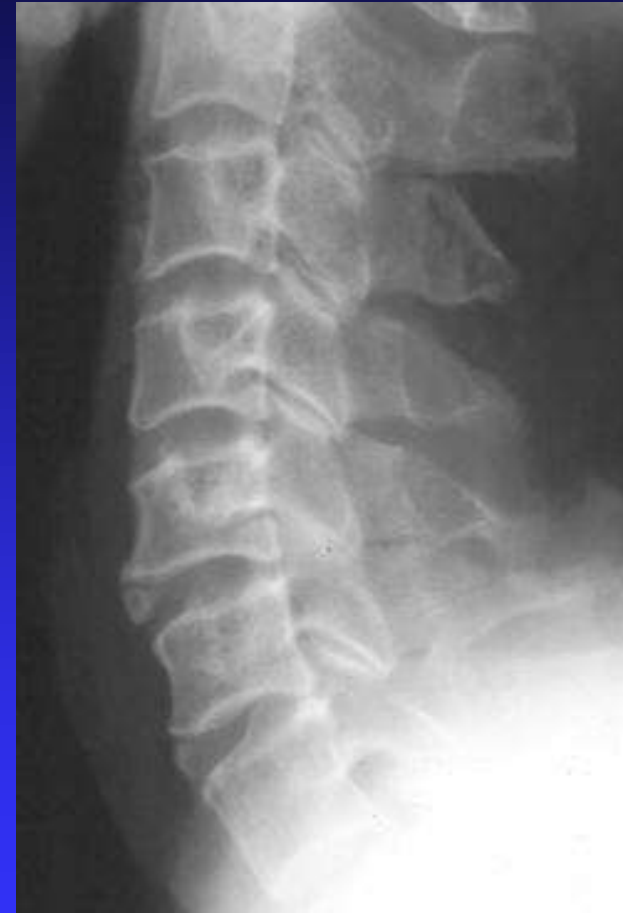History: 38 year-old male with chronic neck pain.

What is your differential diagnosis & How are you going to manage this patient?



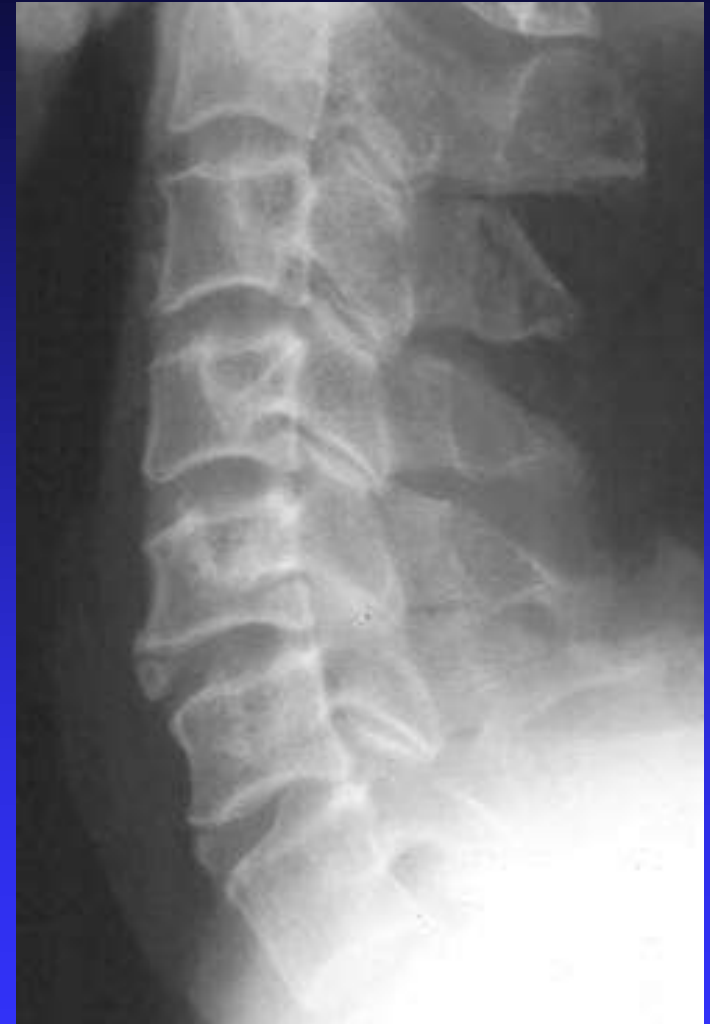Findings

- Generalized osteopenia
- Multilevel facet arthrosis
- Multilevel degenerative disc disease with anterior intercalary bone at C5-C6 level
- Degenerative retrolisthesis at C3



Diagnosis

- Calcification of the annular fibers=
Intercalary Bone
- Sign of degenerative disc disease versus inflammatory disease



Follow-Up

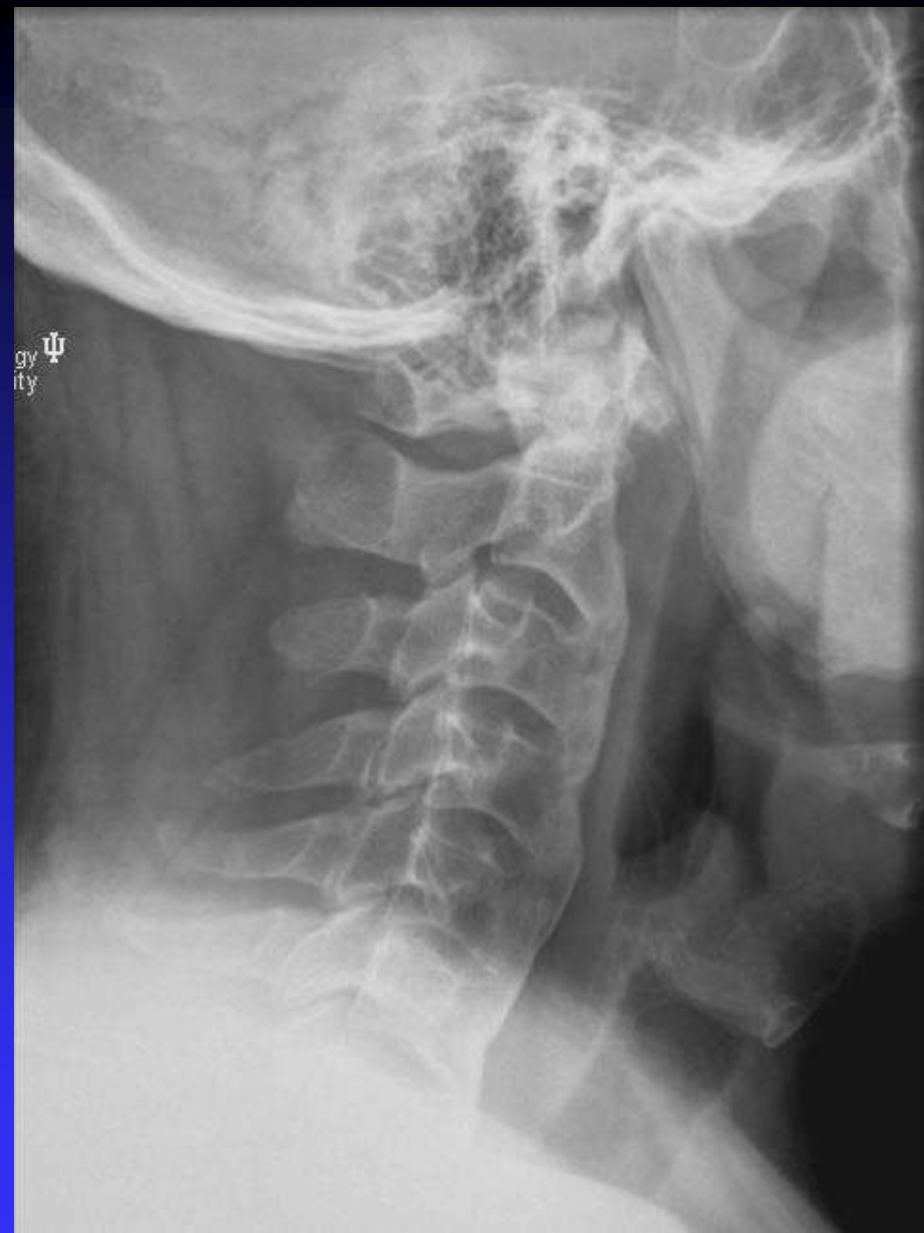- More xrays! More history!
 - Lumbar and pelvic radiographs
 - Evaluate SI joints for erosive changes to indicate inflammatory process.
- Laboratory studies
 - HLA-B27

Chiropractic Treatment

- If inflammatory, need to assess the upper cervical spine for laxity

Case

50 year-old
male; distance
runner with
chronic neck
pain



Findings

- Thick ossification of the anterior longitudinal ligament
- Mild facet degeneration.
- Disc narrowing at C5-C6
- Hypolordosis with anterior shift in weightbearing.

Diffuse Idiopathic Skeletal Hyperostosis- DISH

- Common in thoracic and lumbar spine.
 - Right sided in the thoracic spine.
- **Associated with diabetes mellitus**
- Complications- cervical spine
 - Dysphagia

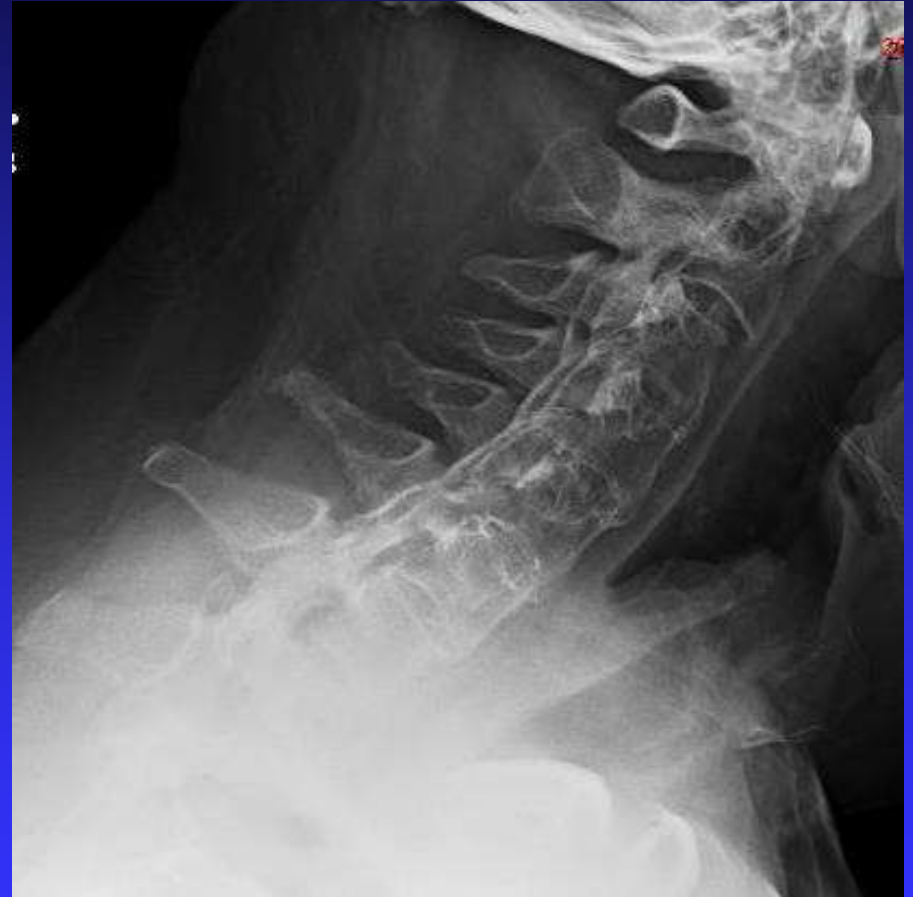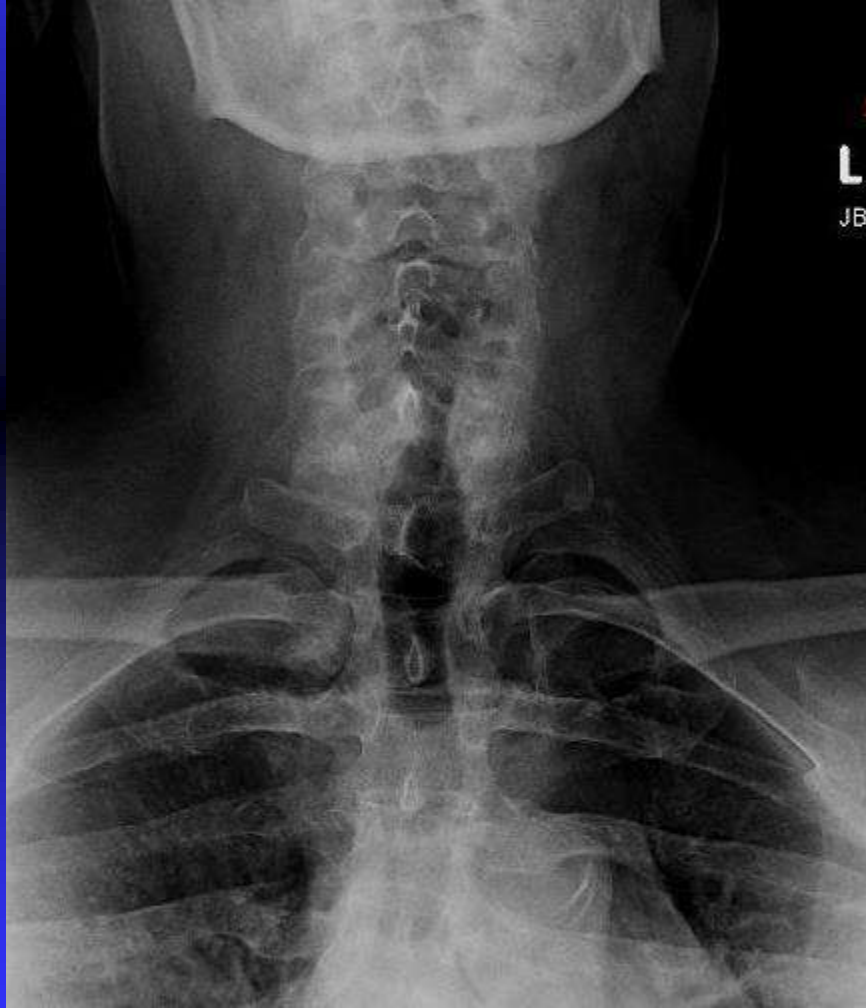
Diffuse Idiopathic Skeletal Hyperostosis- DISH

- Complication- dysphagia
- Common in thoracic and lumbar spine.
 - Right sided in the thoracic spine.
- OPLL- ossification of the posterior longitudinal ligament is possible
 - Can result in spinal canal stenosis

Case

- Chronic pain

Misdiagnosed as DISH—what is it?

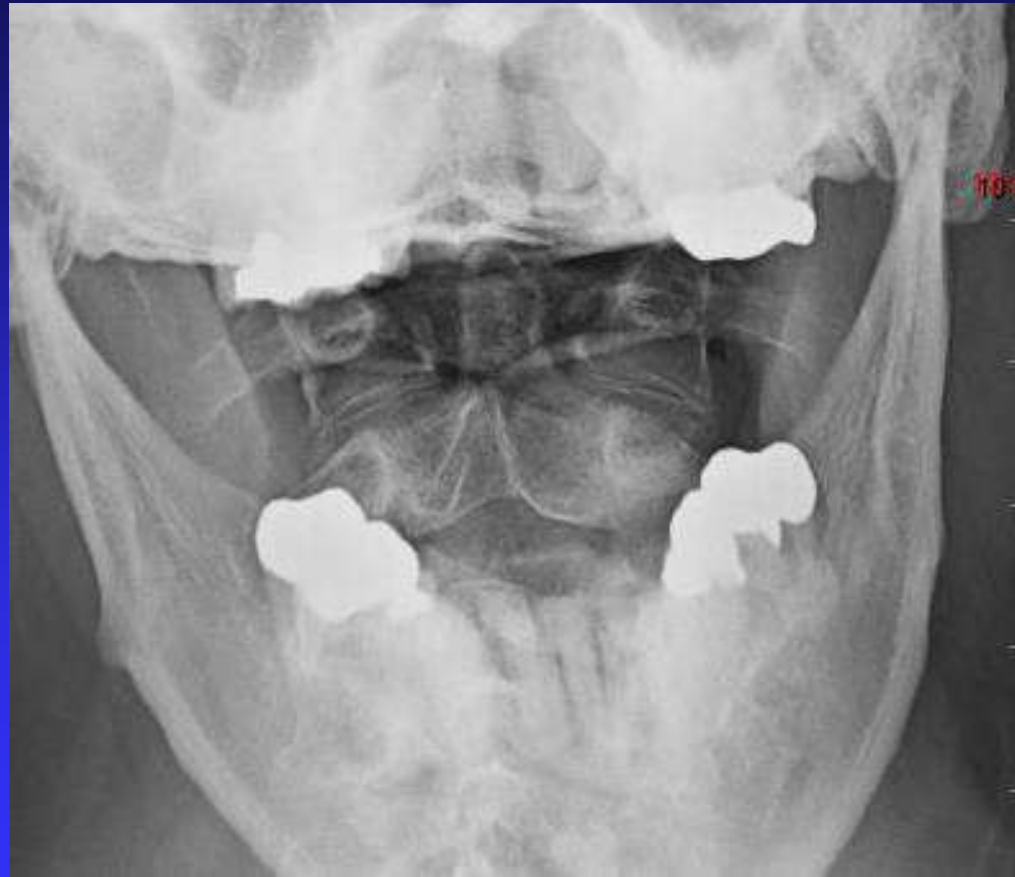

Findings/Diagnosis

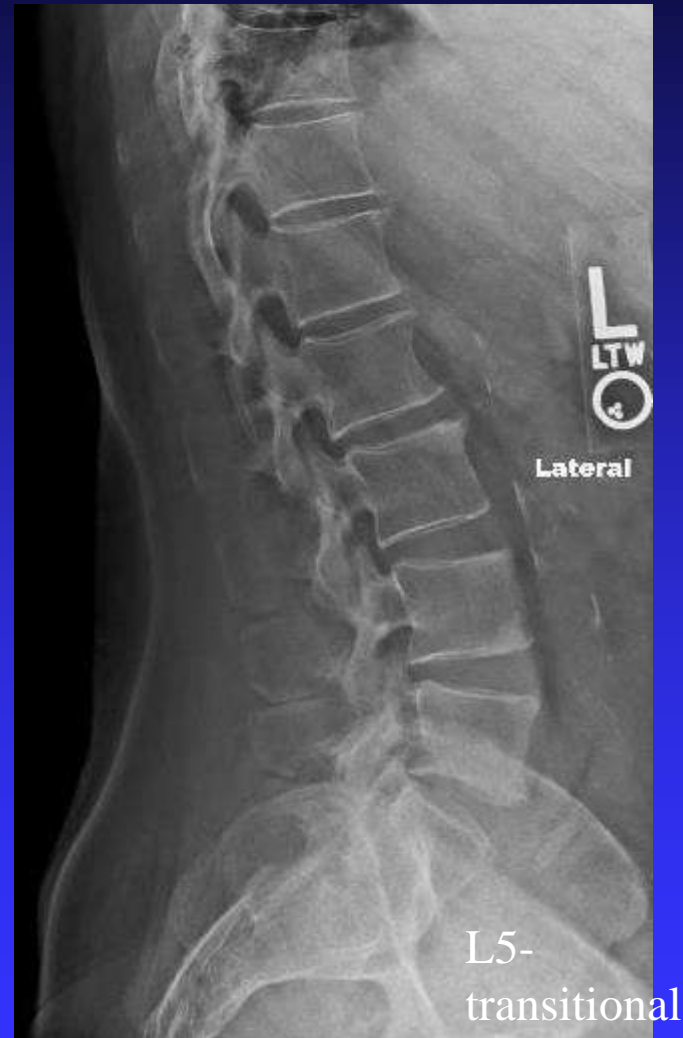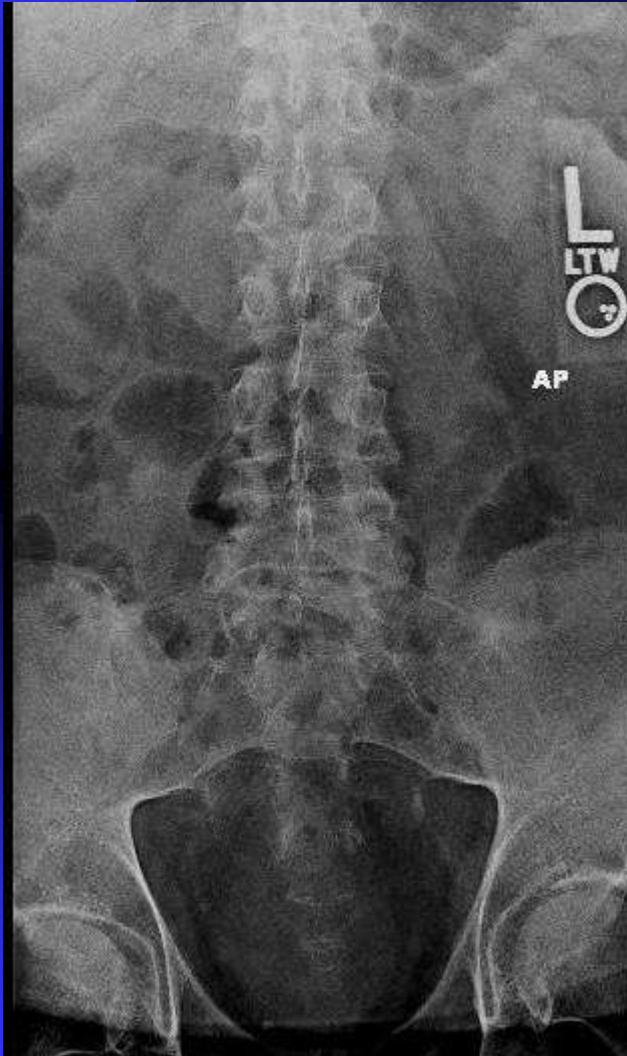- Severe osteopenia
- Anterior shift in weightbearing
 - Cervical & upper thoracic tilt to the left
- Facet fusion
- Anterior spinal fusion, thin ossification of the annulus fibrosus.

AP open mouth

- Fusion at the C1 lateral masses to C2.
- Occiput low on right; rotation of C2.



2 years ago-Lumbar Spine Xrays

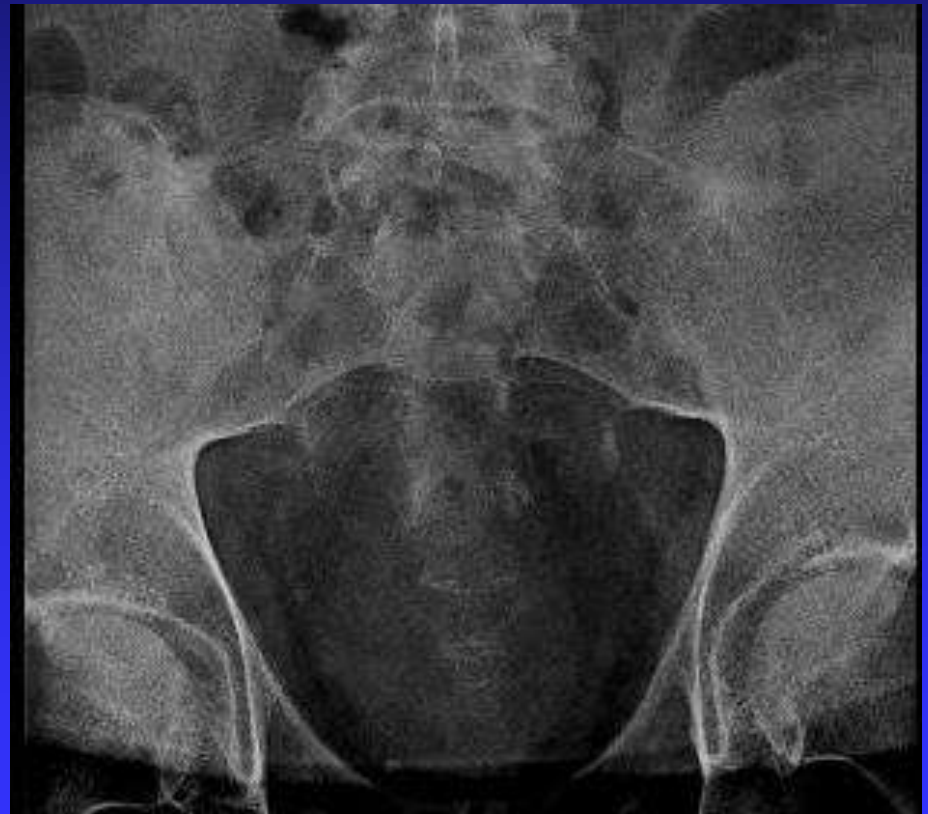

Findings

- Transitional segment at L5 (Sacralization)
- Degenerative changes of lumbar spine
- Bilateral hip arthrosis
- Atherosclerosis of abdominal aorta

Findings

- Fusion of bilateral sacroiliac joints>>>>Ankylosing Spondylitis

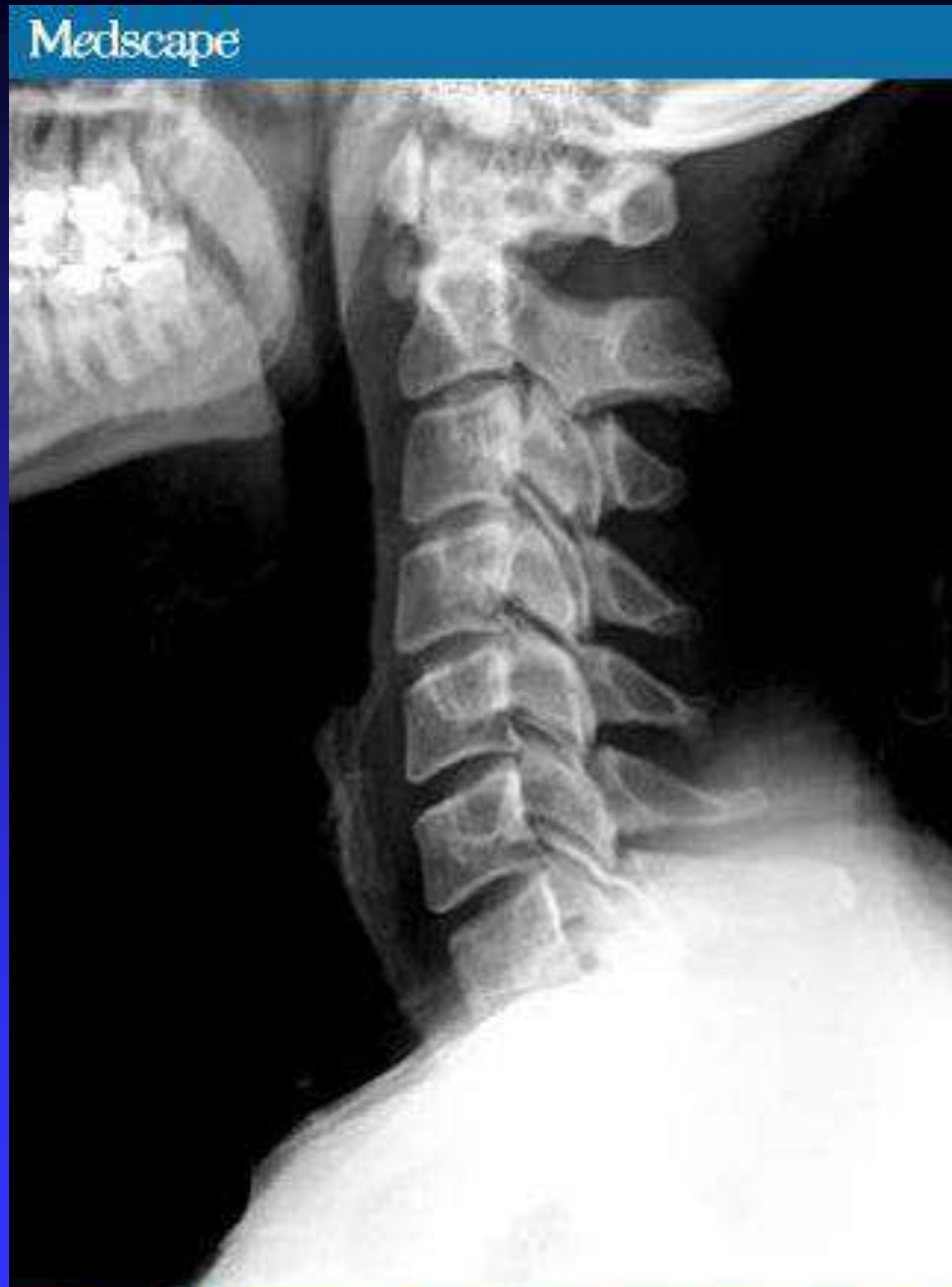

Ankylosing Spondylitis: Follow-up

- Rheumatologist & Laboratory studies
 - HLA-B27

Case

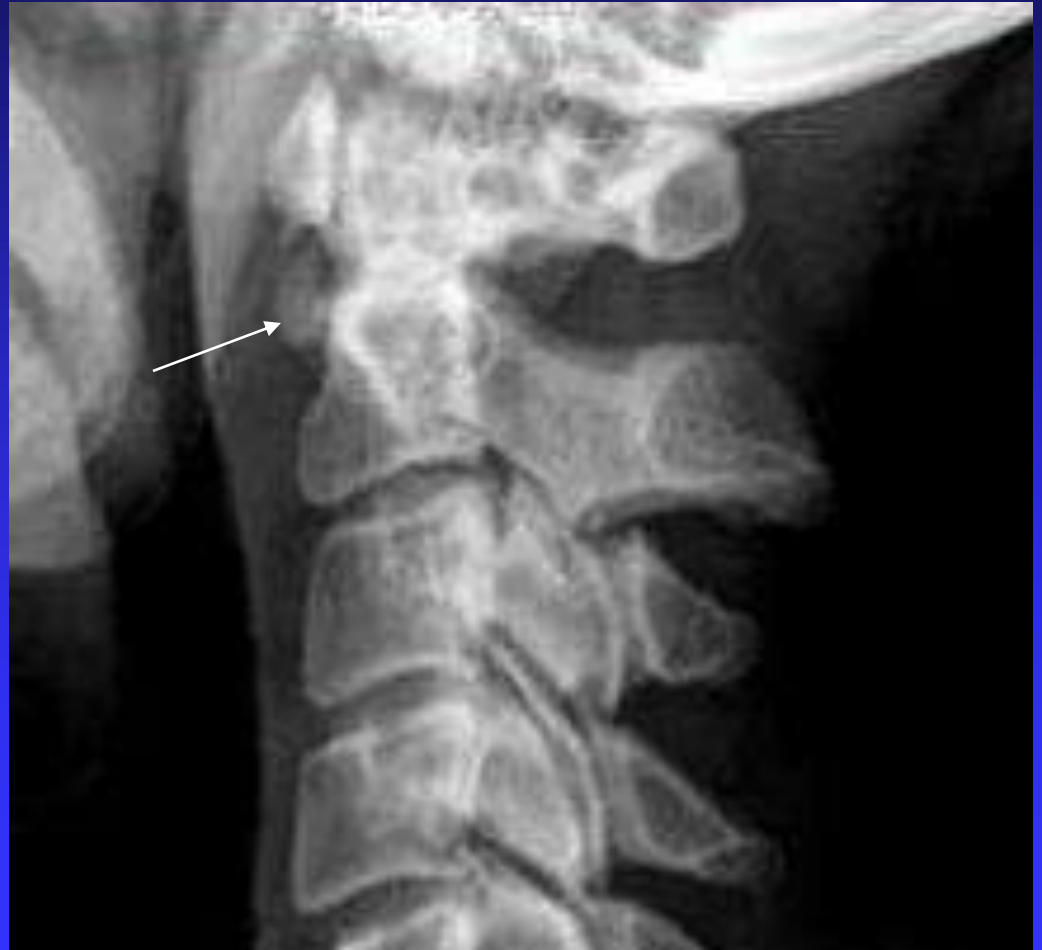History: pain, stiff neck, muscle spasms; trauma with hyperextension



Findings

Radiopacity subjacent to the anterior tubercle of C1

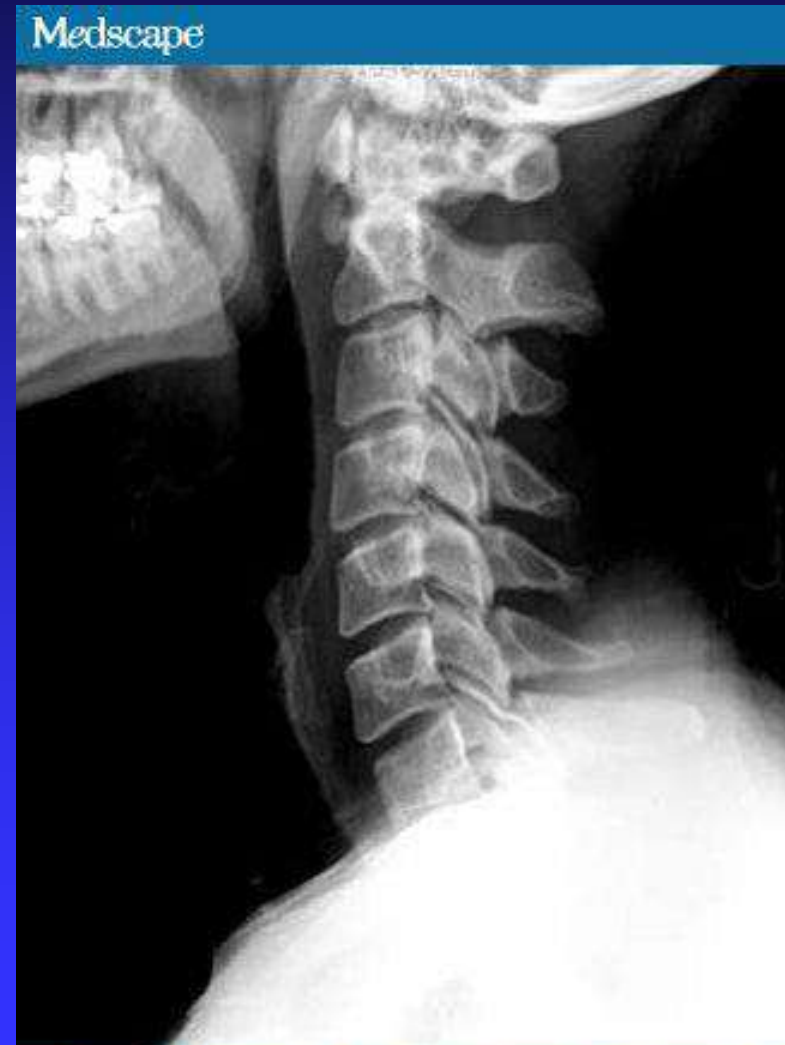There is extension of the upper cervical spine; there is no fusion or occipitalization. Mastoid air cells overlies C1.



Hydroxyapatite Deposition Disease of the anterior longus colli tendon

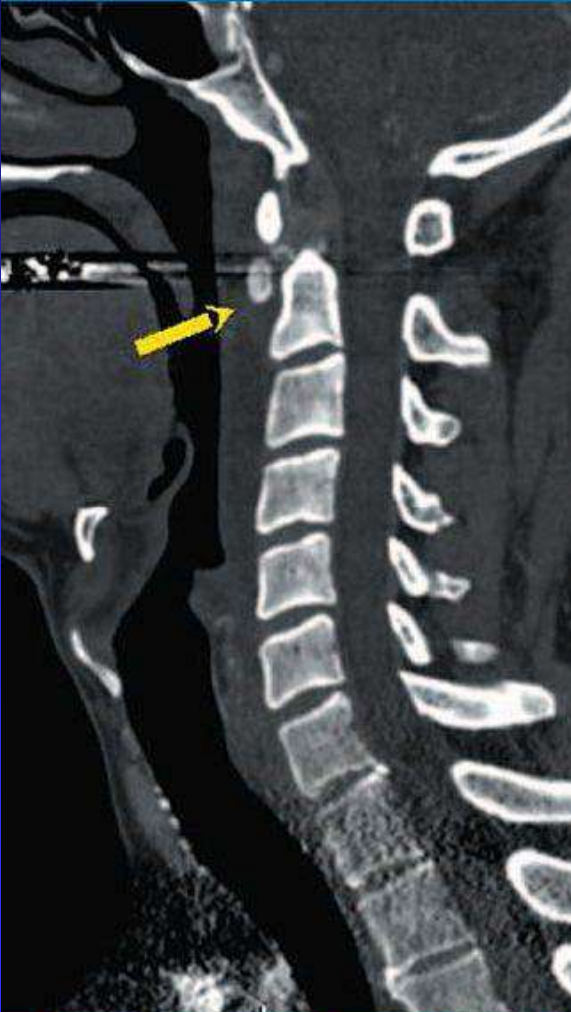Aka calcific tendinitis

- Occurs due to trauma
- **Self limiting 1-2 weeks; it will reabsorb and go away.**



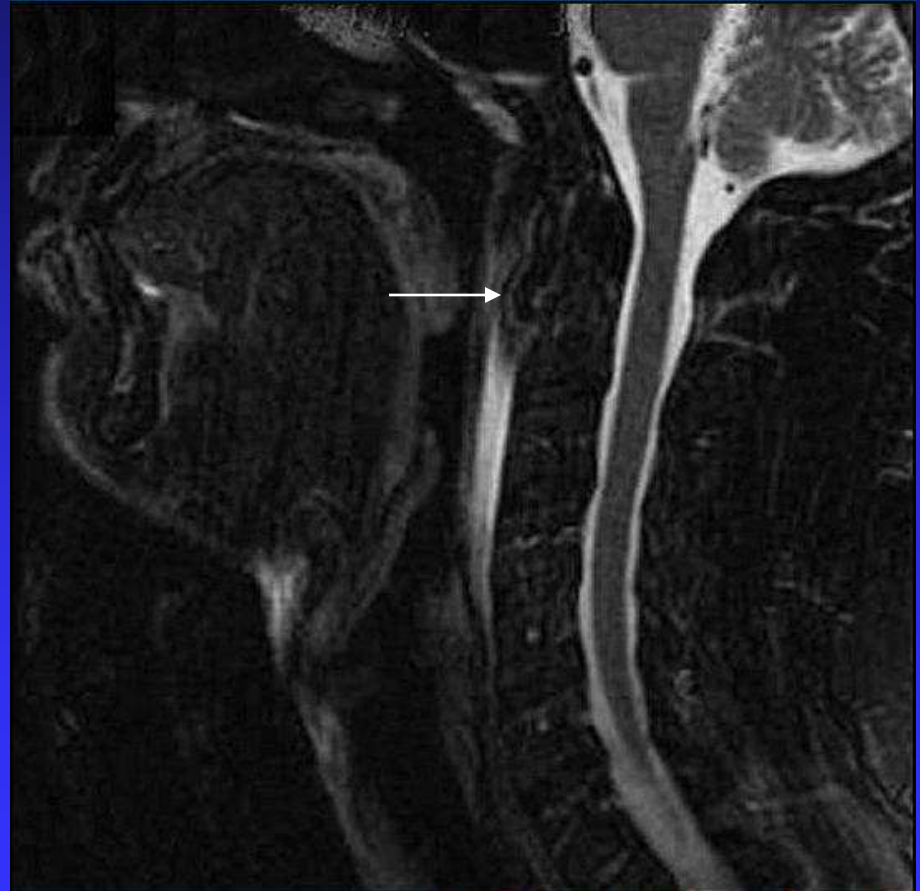
Sagittal Reformatted CT and Sagittal T2 weighted MR images

Medscape



Source: Appl Radiol © 2009 Anderson Publishing, Ltd.

Medscape



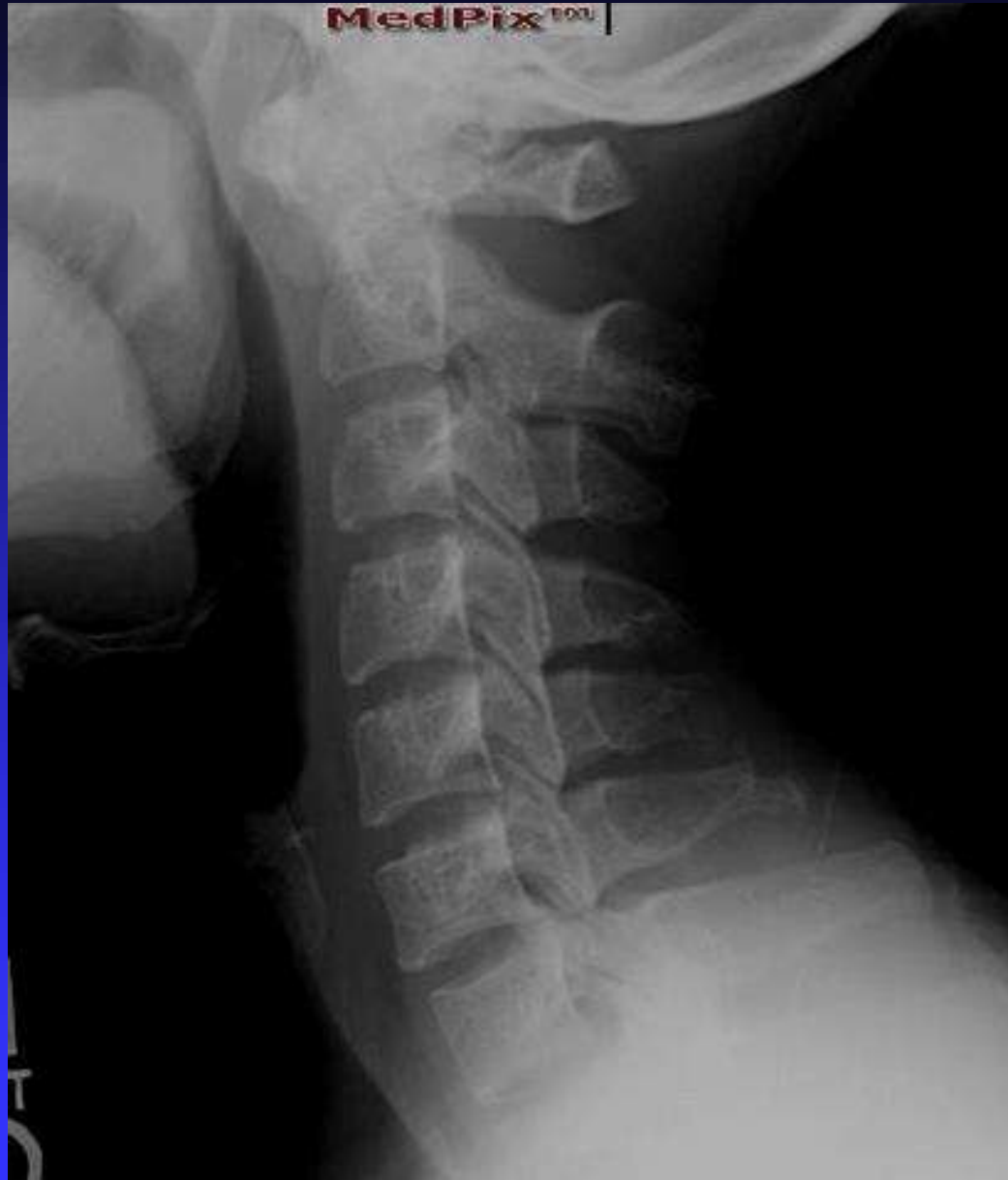Source: Appl Radiol © 2009 Anderson Publishing, Ltd.

Calcific Tendinitis of Cervical Spine

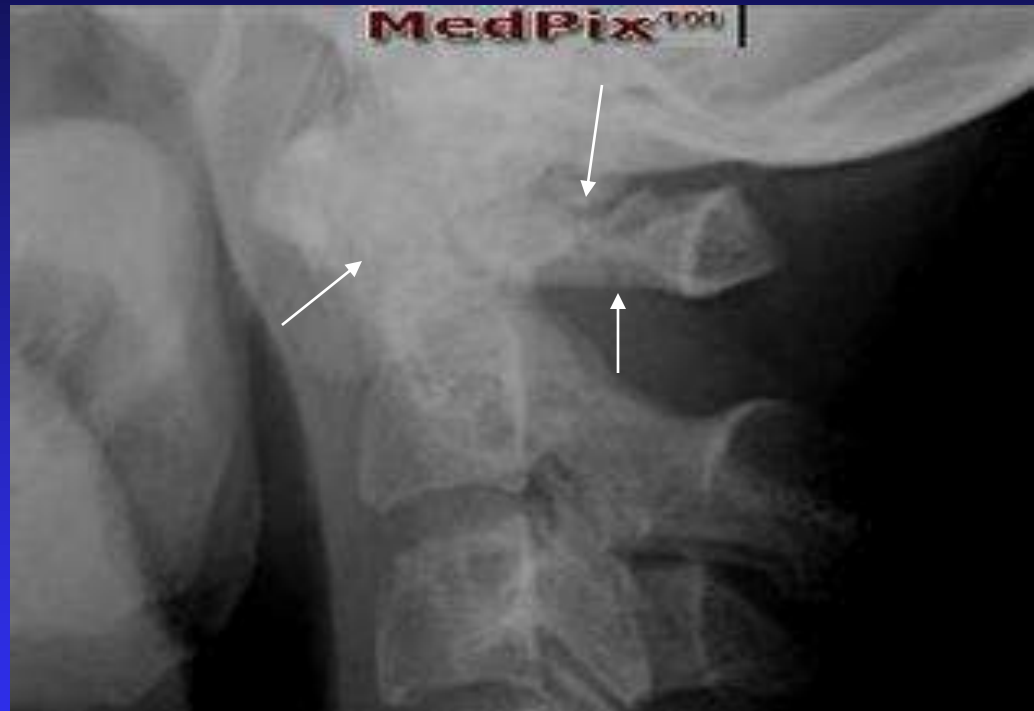- The calcific matrix will absorb and disappear. It is made of a toothpaste consistency.
- No need for CT or MRI
 - CT: shows bony detail
 - MRI: shows what's inside the bone and soft tissue pathology

Case

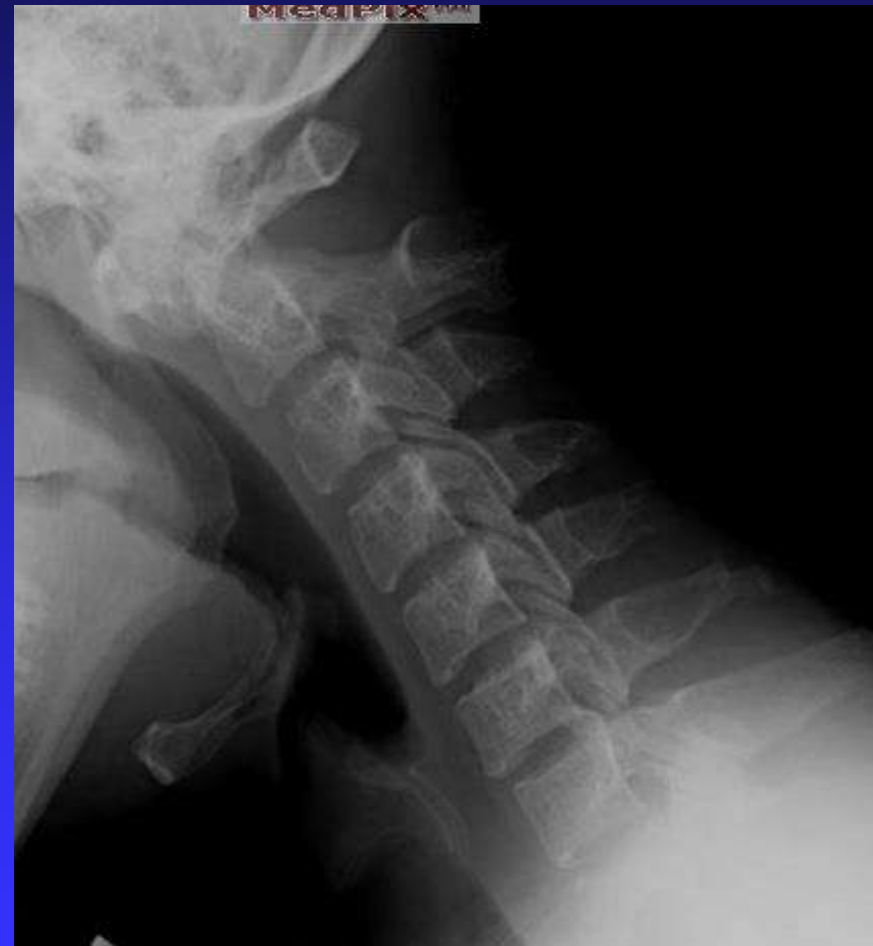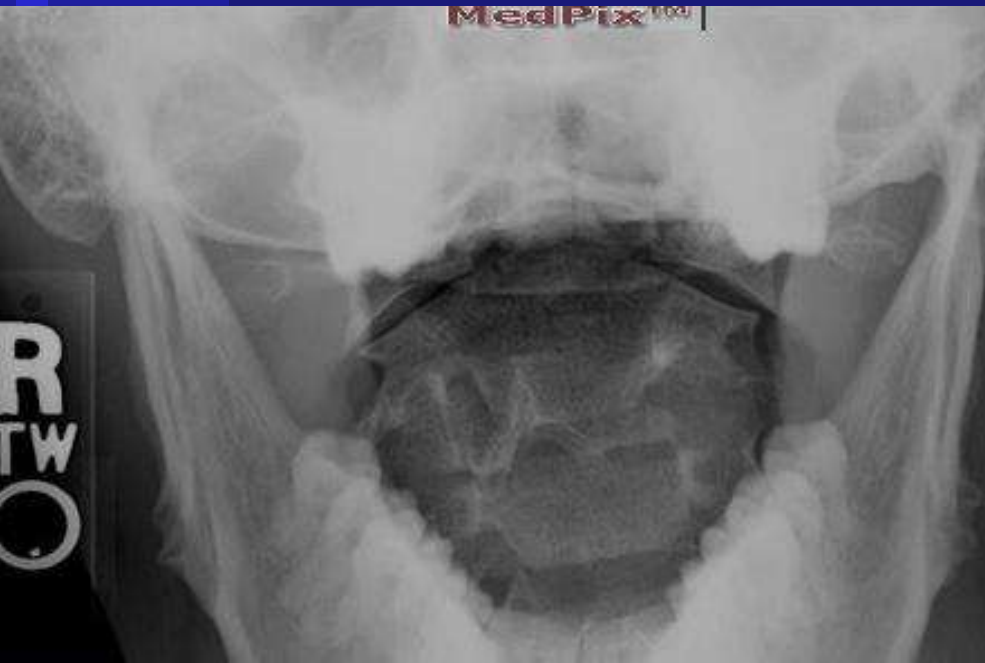Hx: suboccipital pain, headaches, and neck stiffness.



- **Posterior arch fracture** at C1
- **Type 2 odontoid fracture**
- Moderate prevertebral soft tissue swelling, overlying the dens
- Associated with rupture of the transverse ligament

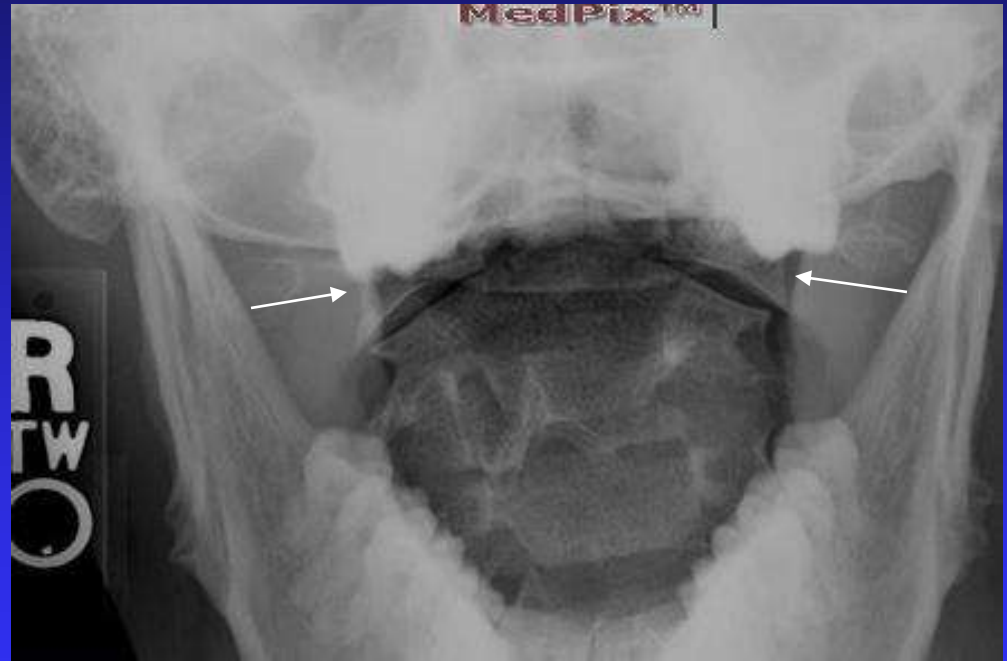


APOM & Lateral Flexed Views



AP open mouth

Lateral masses of C1
bypass the lateral
margins of C2=
Burst fracture of C1



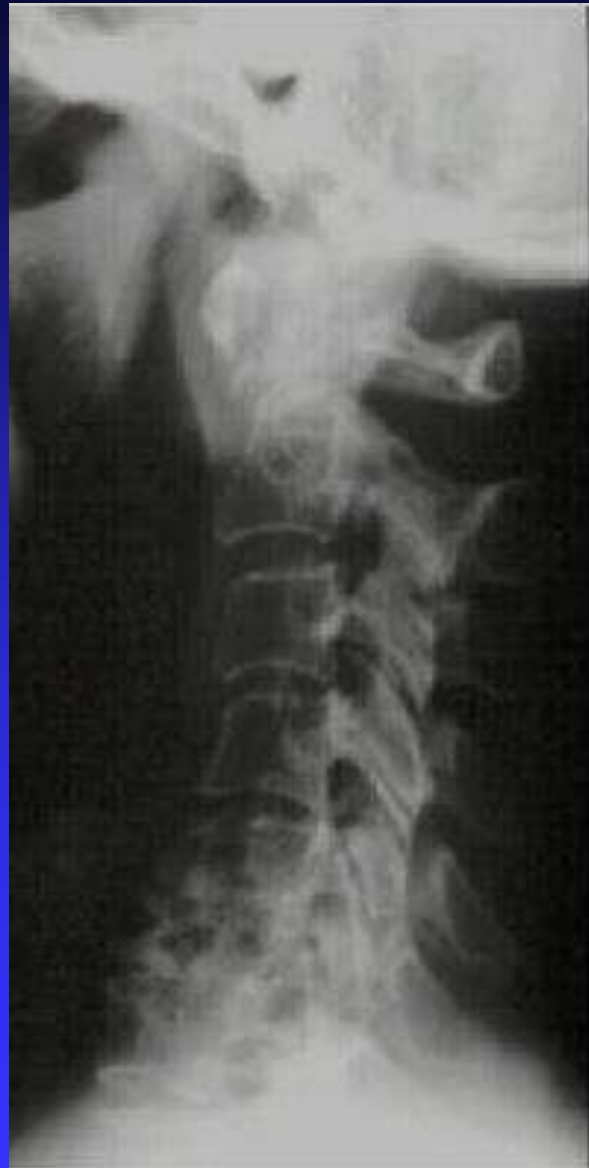Jefferson Burst Fracture of C1

- 2 or more breaks of the ring of the atlas
 - Most common to fracture adjacent to the lateral masses; bilateral > unilateral and the fracture is anterior and posterior to the lateral masses.
- Mechanism of Injury: **Compressive injury**

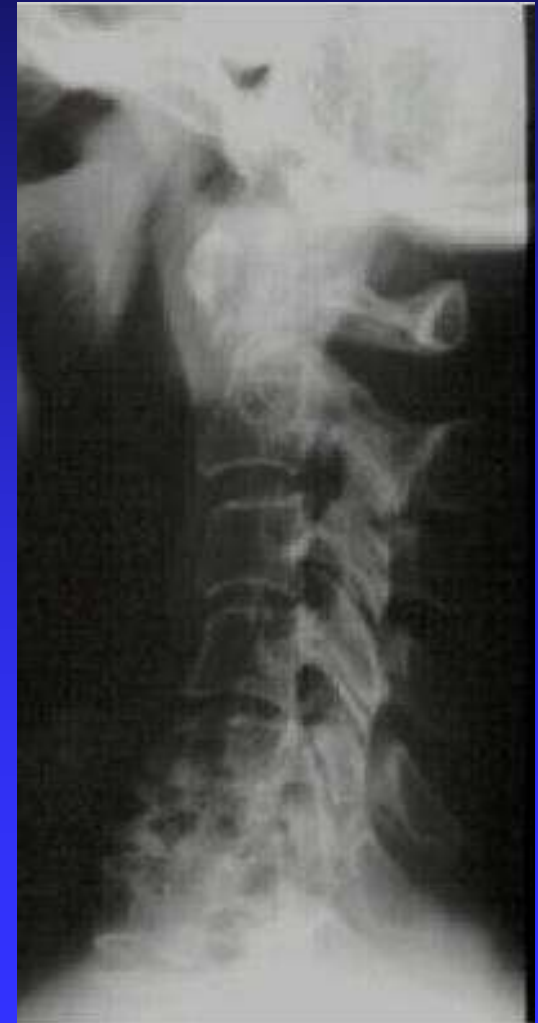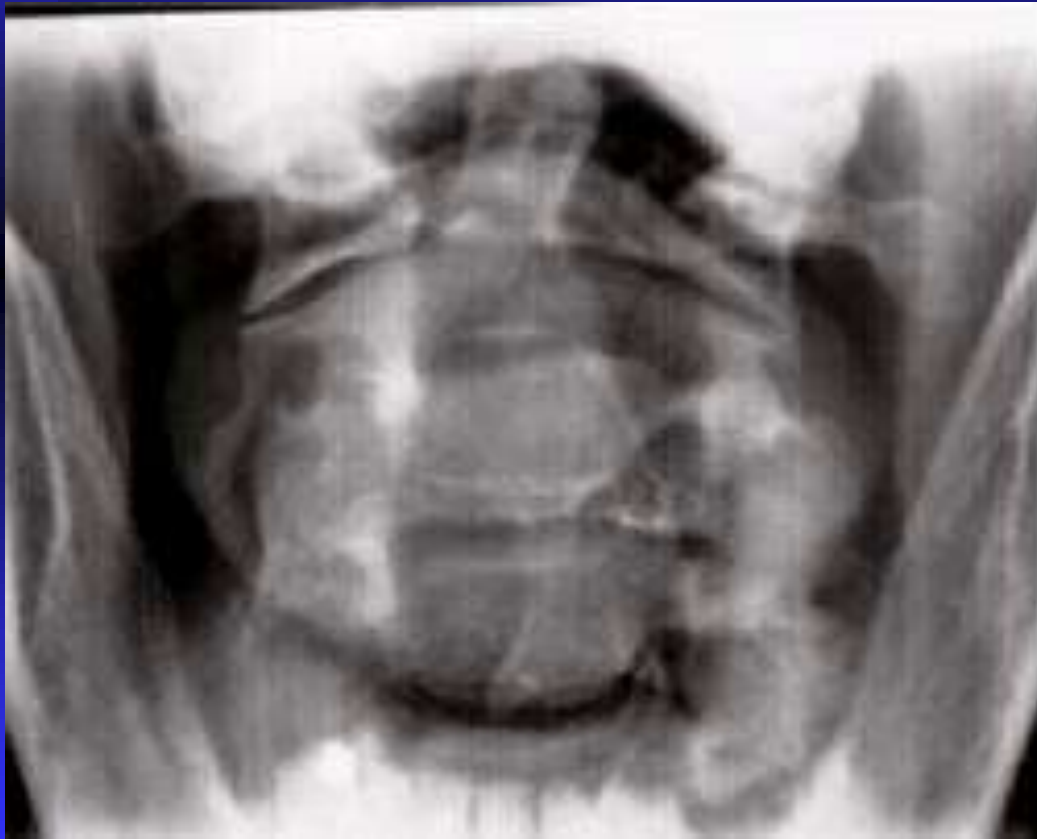
Case

I know this is not the best xray...ignore everything below C4. Patient had trauma.

Where is the fracture?

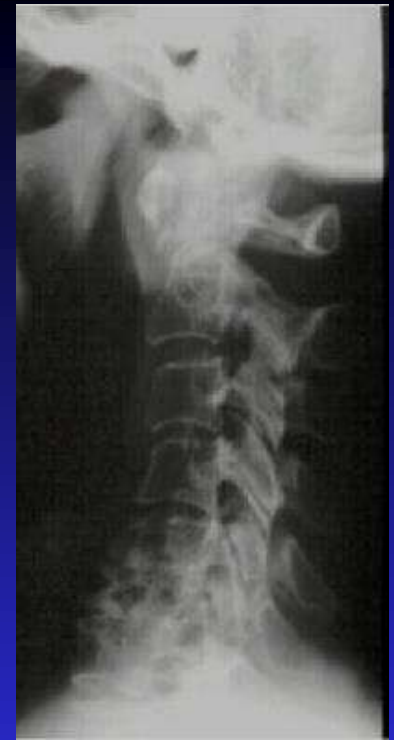

APOM & Lateral Neutral Views



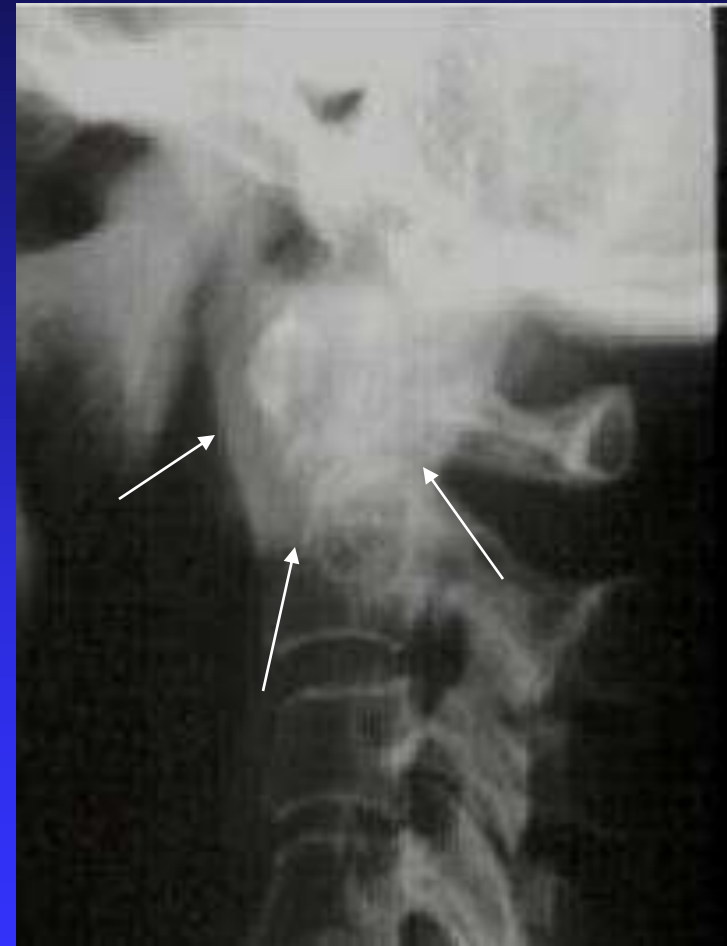Findings

- Straightening of the cervical lordosis
- Generalized osteopenia
- Degenerative disc disease & Facet arthrosis
- Fracture and Angulation of the dens
- Soft tissue swelling of upper cervical>>>This is NOT a gigantic earlobe☺



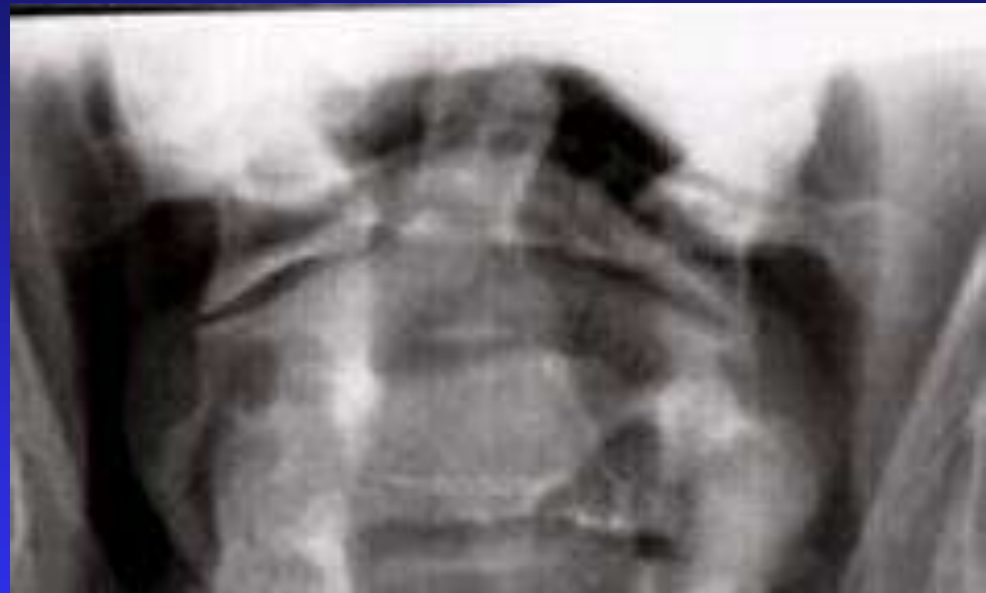Findings

- Soft tissue edema
- Widened Atlantodental interspace

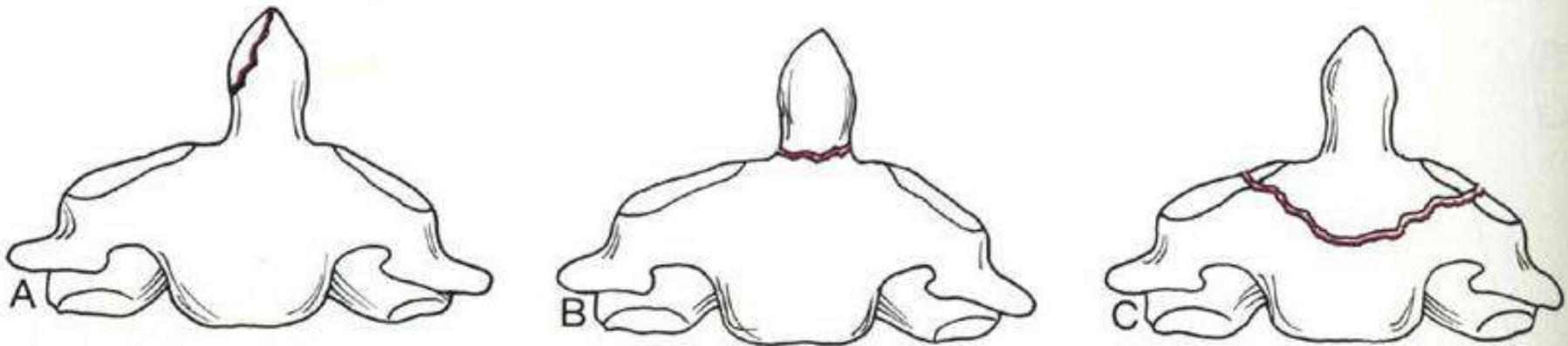


Odontoid Fracture: Type 2

- Type 2: fracture at the junction of the **base** of the dens and body of the axis
- **Lateral tilt of the dens**
- Most common fracture of C2 & Complication is **non-union**
- **Note: Lateral masses are intact and do NOT bypass the C2 body**



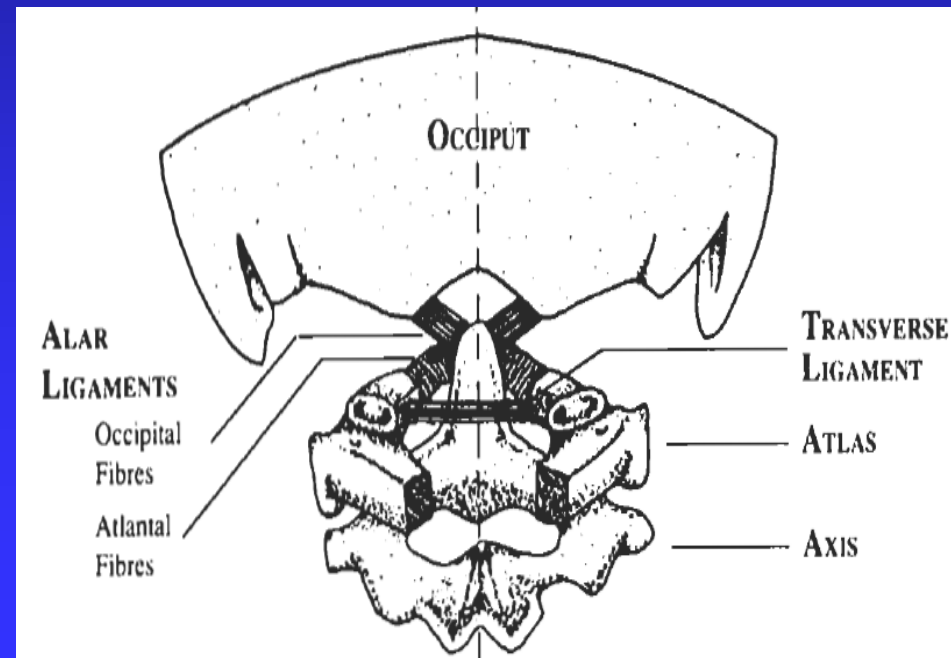
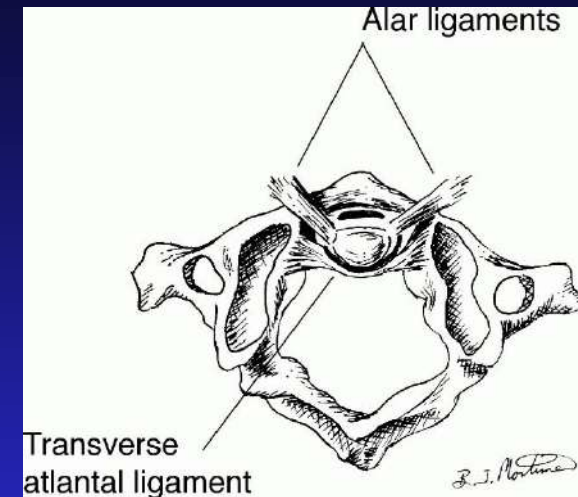
- Type 1- Avulsion; majority are stable
- Type 2- Nonunion complication
- Type 3- Vertical fracture through the body of C2; heals rapidly.



ANDERSON AND D'ALONZO CLASSIFICATION OF ODONTOID FRACTURES. A. Type I. B. Type II. C. Type III.

Type 1 Odontoid Avulsion Fracture

- Type 1= oblique fracture/avulsion of the odontoid by the alar ligament
- Associated with rotation and whiplash forces
- Alar ligament limits rotation and lateral flexion, *contralateral* side of the craniovertebral complex.

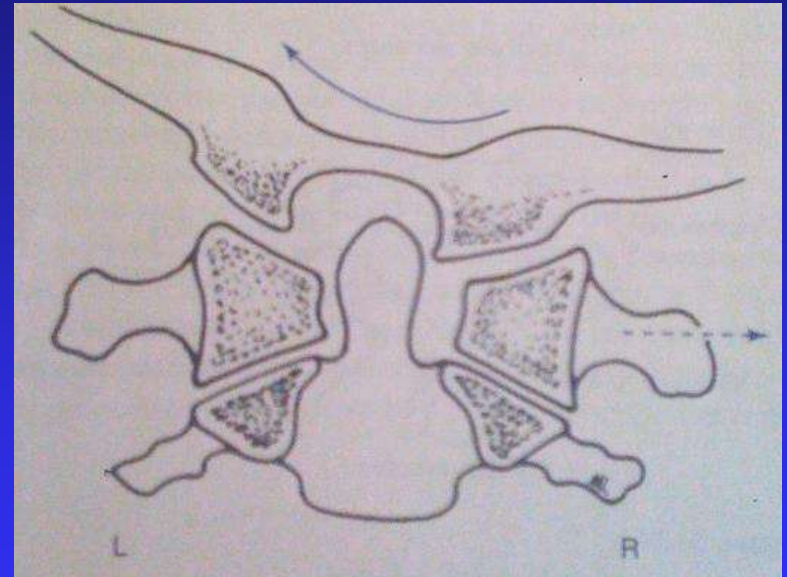


Radiographic Evaluation of the Alar Ligament

- Alar ligament attachment sites are the occipital condyle and superior-lateral aspect of the dens.
- APOM view
 - Majority are normal
- **Evaluate Alar ligaments** by AP open mouth with right and left lateral flexion/bending
 - Right lateral flexed position= evaluates the left alar ligament
 - Example: In right lateral flexion, C1 displaces laterally away from dens on the right pass the C2 vertebral body margins= **left alar ligament disruption.**

Making Sense of It

- Normal motion: right lateral flexion of CO-C1 & C1-C2, approximate right condyle to dens and increased ADI on the right
 - Opposite slide & roll due to convex condyles and concave lateral masses of C1.
- Disrupted alar ligament on the left would allow more rolling of the condyle to the left and more right lateral sliding of C1 pass the C2 margins.
- Intact alar ligament would rotate the C2, deviating the spinous process away from lateral flexed side.

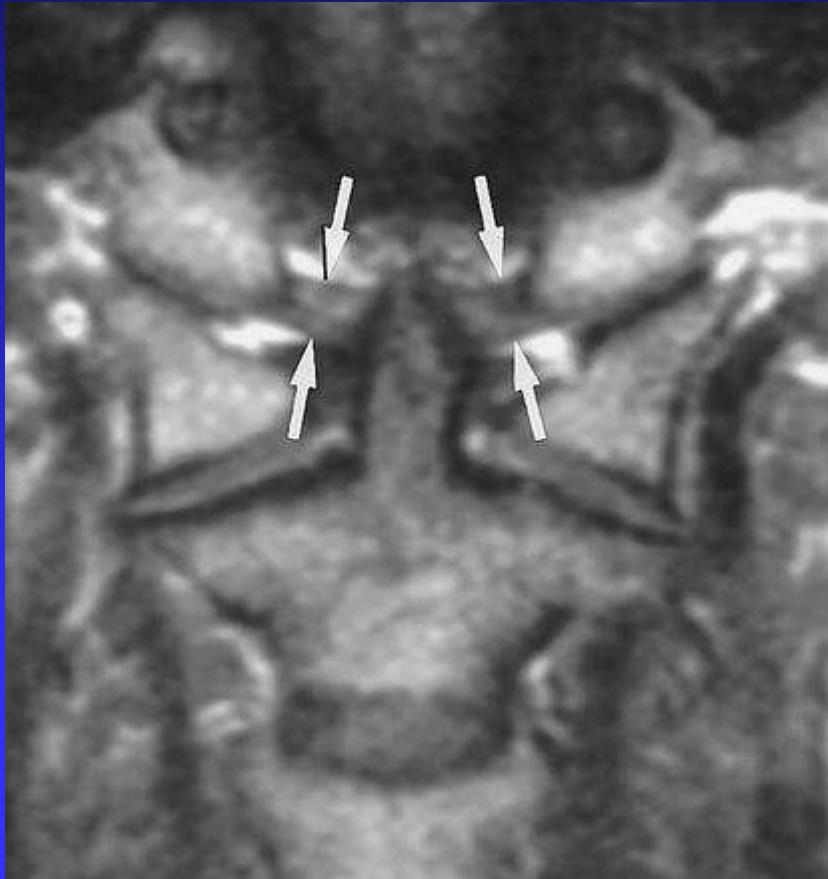


Bergmann & Peterson, Chiropractic
Technique, 2nd Ed; 2002

Alar Ligament Rupture

- Atlanto-occipital instability
- MRI: evaluate the upper cervical spine ligaments (separate protocol from the cervical spine MRI by the imaging center)

Normal Alar Ligaments on Coronal T1 weighted MR image

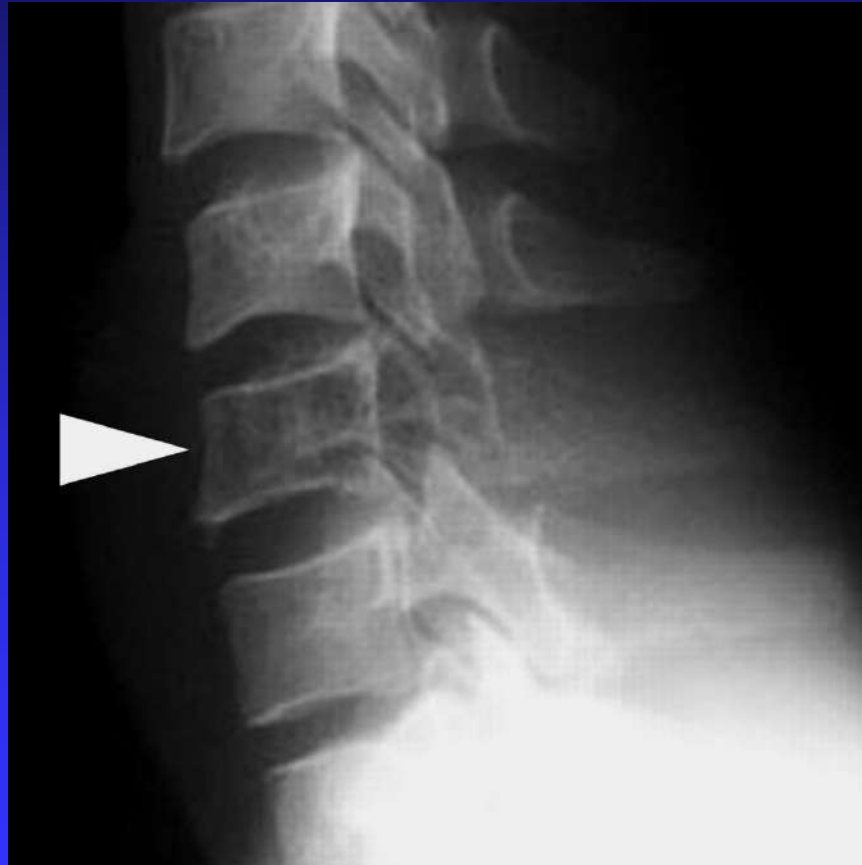

Protocol:

Coronal, axial and sagittal images; 2.0-mm slice thickness

Alar ligament attachment sites are the occipital condyle and superior-lateral aspect of the dens.

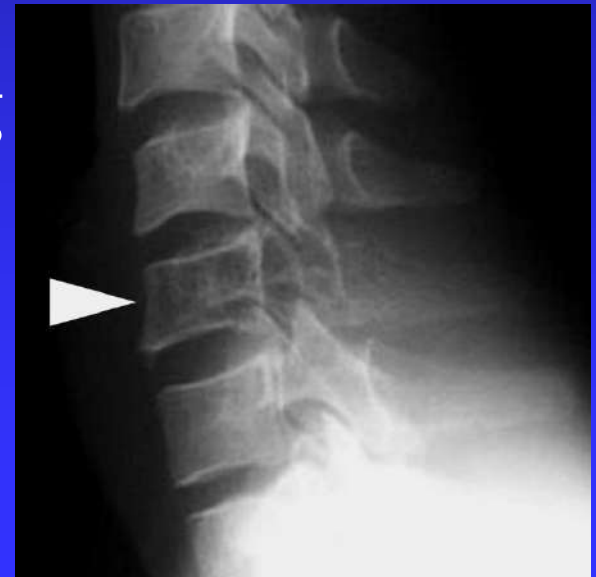Case #6 36 yom neck pain



Rodallec M H et al. Radiographics 2008;28:1019-1041

Findings

- C6: Compression fracture, with osteolytic lesion within the vertebral body, lamina, and indistinct margins of the spinous process.
- What is the next imaging
 - MRI



Differential diagnosis

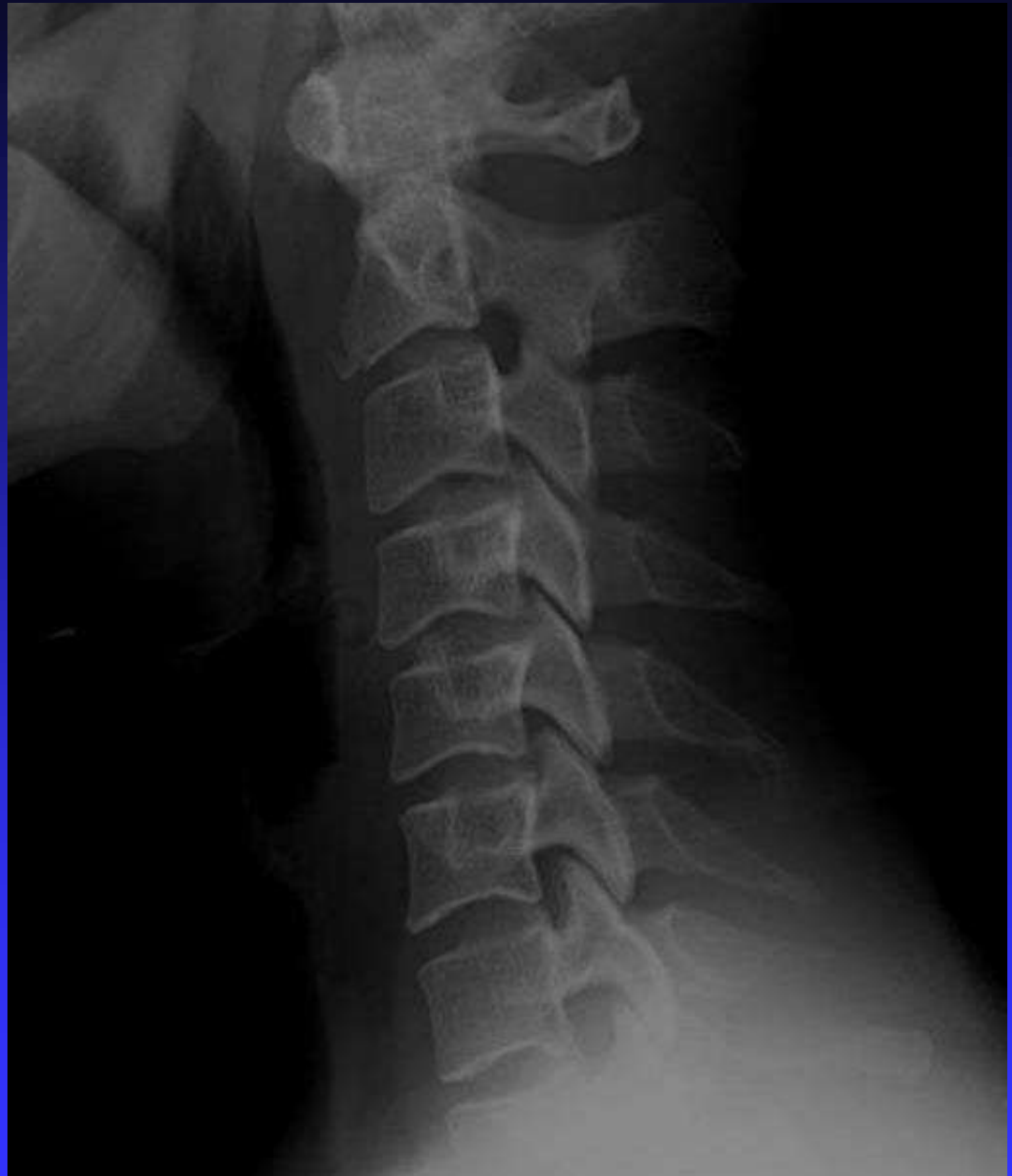- Mets or
- Primary bone tumor

- Dx: After MR and bone scan, etc.....renal cell carcinoma with metastases to the spine.

Case

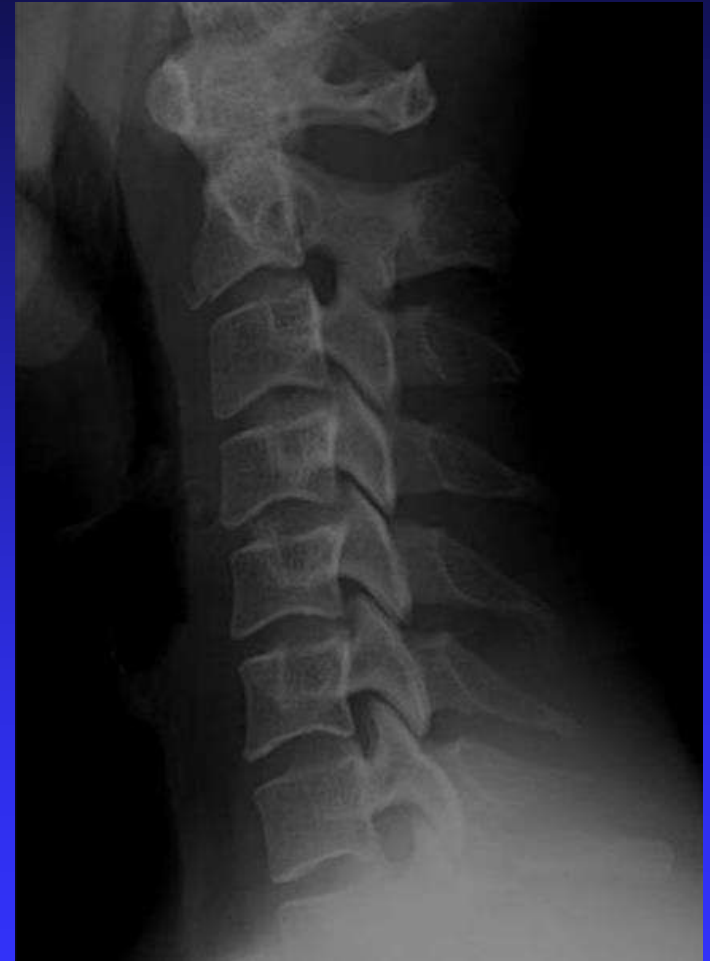Whiplash:
Hyperflexion
and
hyperextension
mechanism of
injury

www.medpix.com



Findings

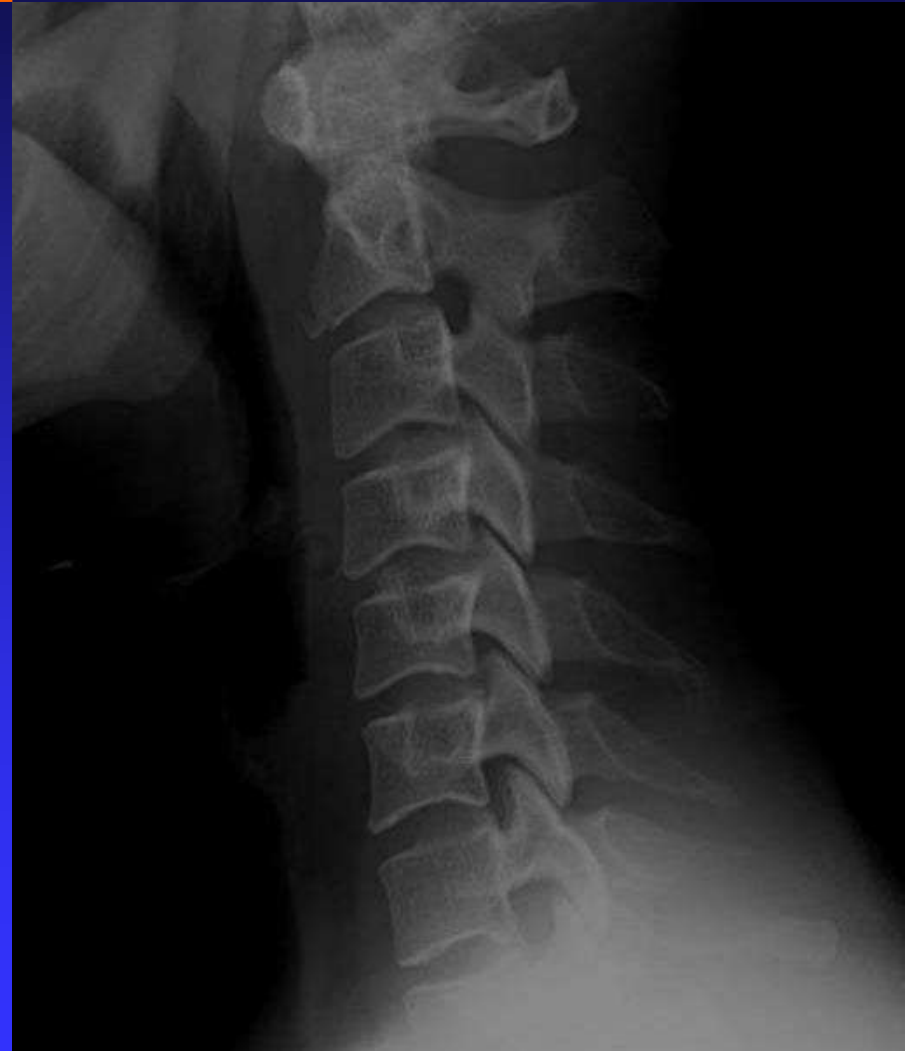- Straightening of the cervical spine
- Posterior ponticle
- Fracture or avulsion of the C7 spinous process; and avulsion at the anterior, inferior corner of C2.



Clay Shoveler's Fracture & Teardrop Fracture

Clay Shoveler's at C7

- Avulsion of trapezius and rhomboid tendon on the spinous process
- Cause: abrupt flexion or direct trauma.
- **Fragment typically displaces caudally; stable**



Clay Shoveler's Fracture & Teardrop Fracture

Teardrop Fracture at C2

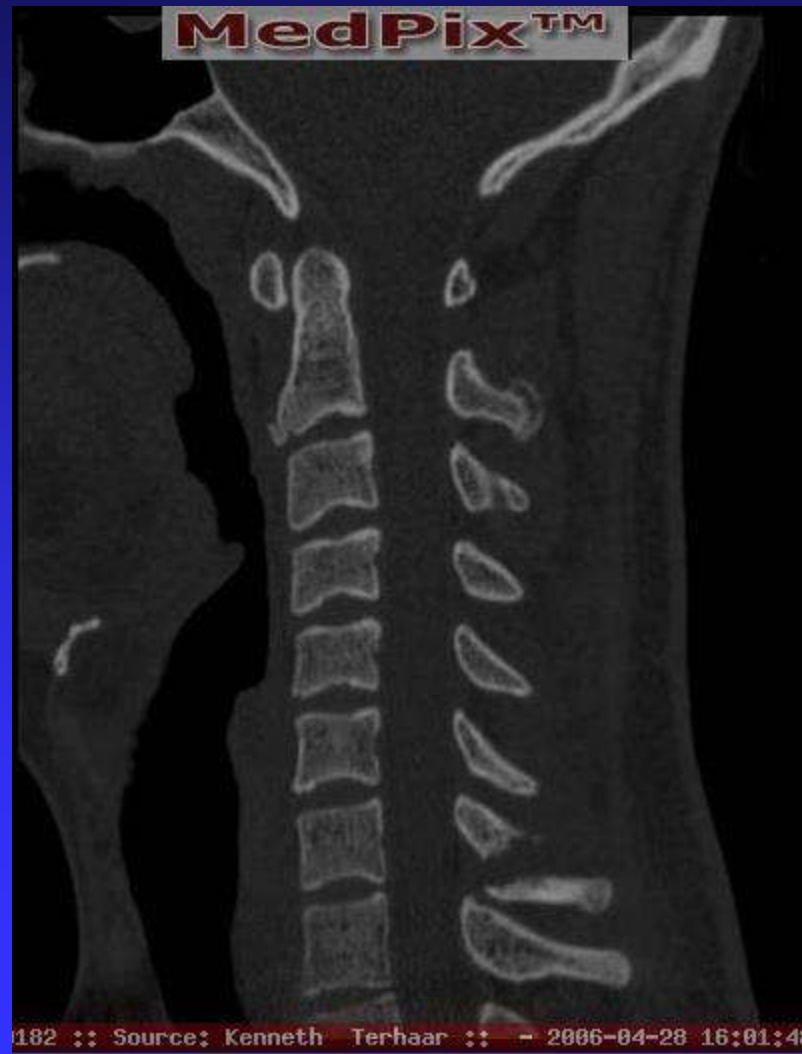- Avulsion of annulus fibrosus
- Cause: Hyperextension of upper cervical spine
- **Fragment is stable;
Tear of the disc at C2-C3**



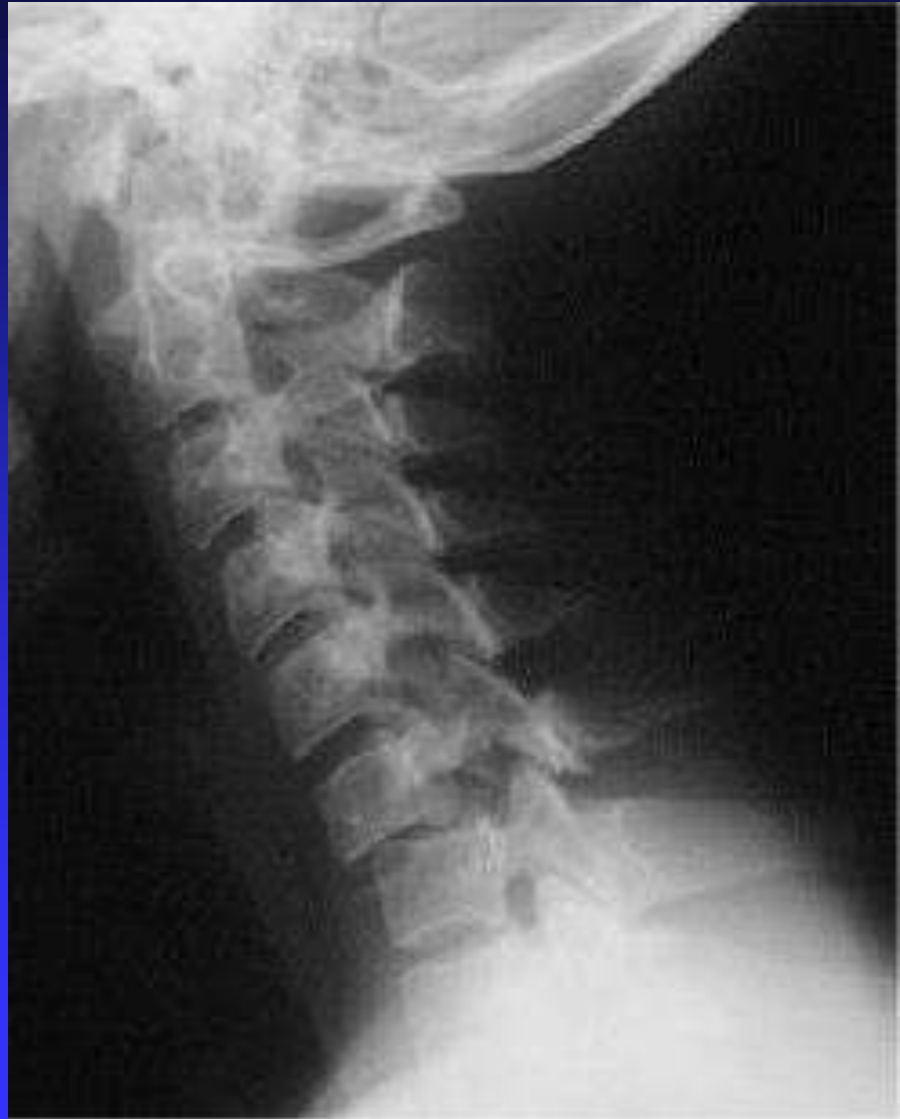Follow-up

- CT imaging for evaluating for more fractures; evaluate the visible fractures seen on the xrays.
- Eventually, MRI to evaluate the disc and soft tissues.

Clay Shoveler's Fracture at C7 Sagittal Reformatted CT Image

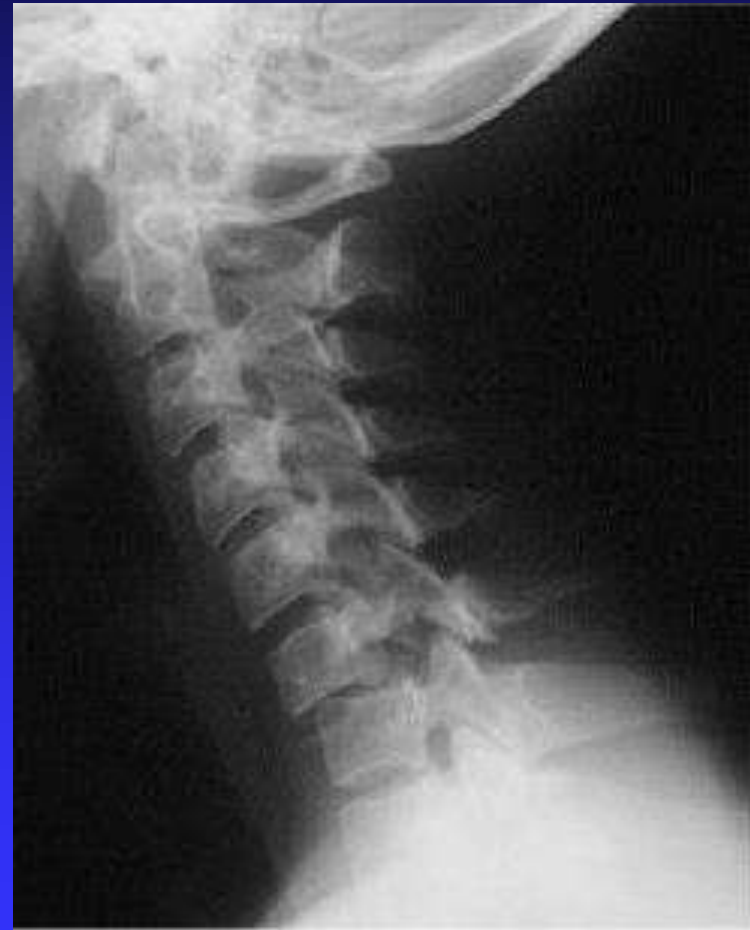

Case



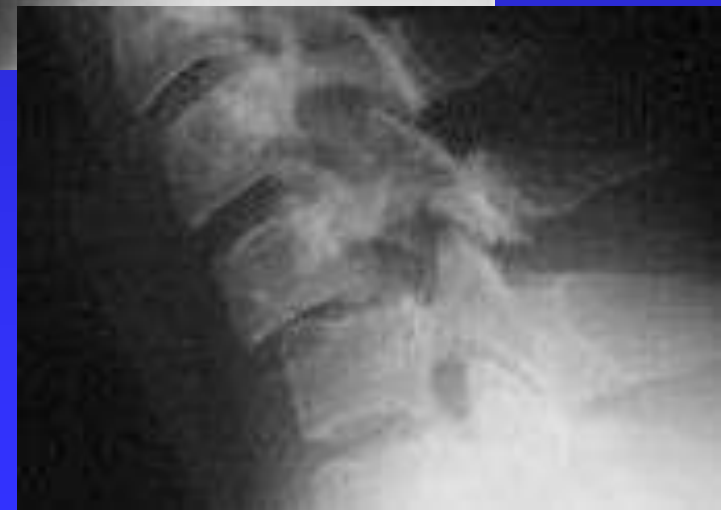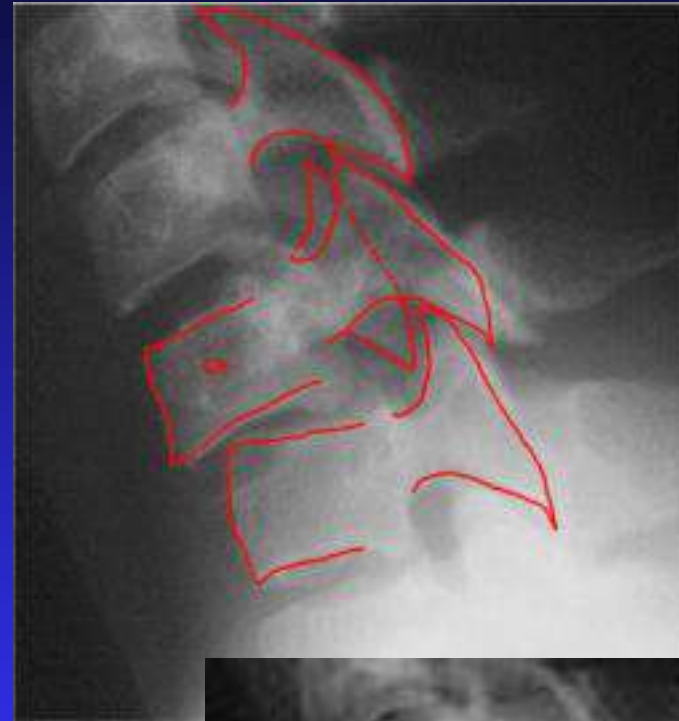
Findings

- Anterior head carriage
- Anterior translation and flexion angulation of the C6 body
- **Widened Interspinous Distance, C6 to C7= injury or disruption of the Interspinous Ligament.**
- Facet dislocation at C6-C7.



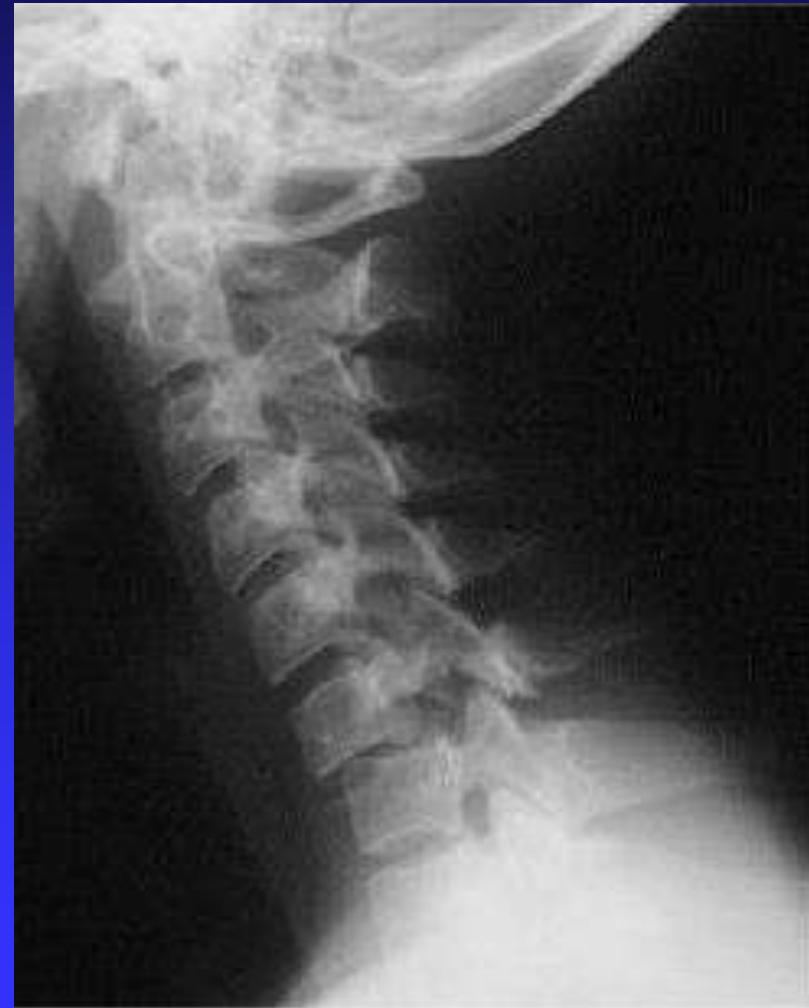Unilateral Facet Dislocation

- Mechanism of Injury:
Flexion & Rotation
- Anterior displacement of
body
- Bow tie sign with
dislocated articular
mass/pillars



Unilateral Facet Dislocation

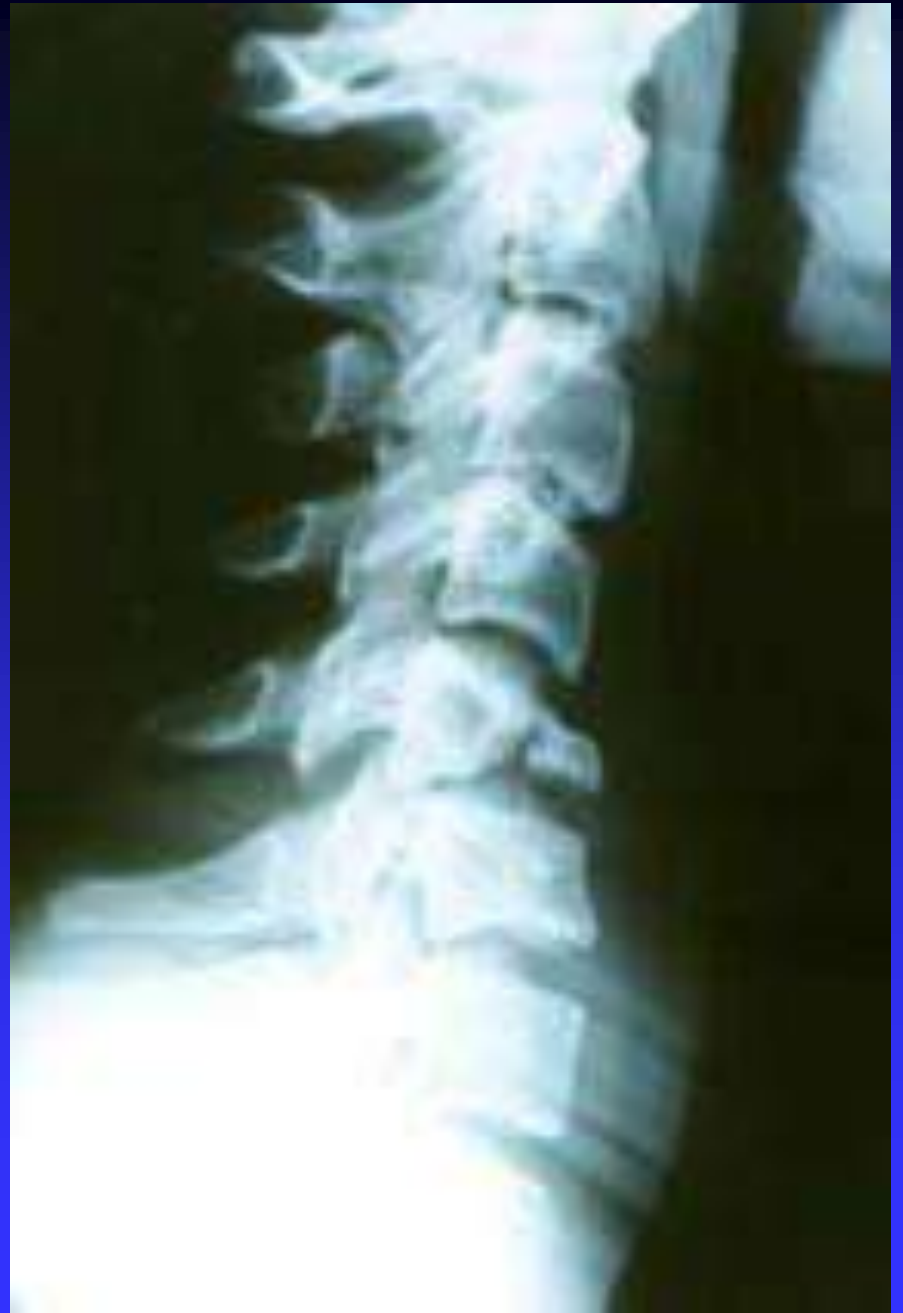- Rupture of interspinous ligament and capsule
- Mild injury to posterior longitudinal ligament and annulus fibrosus
- Bilateral oblique views to identify the dislocated facet joint

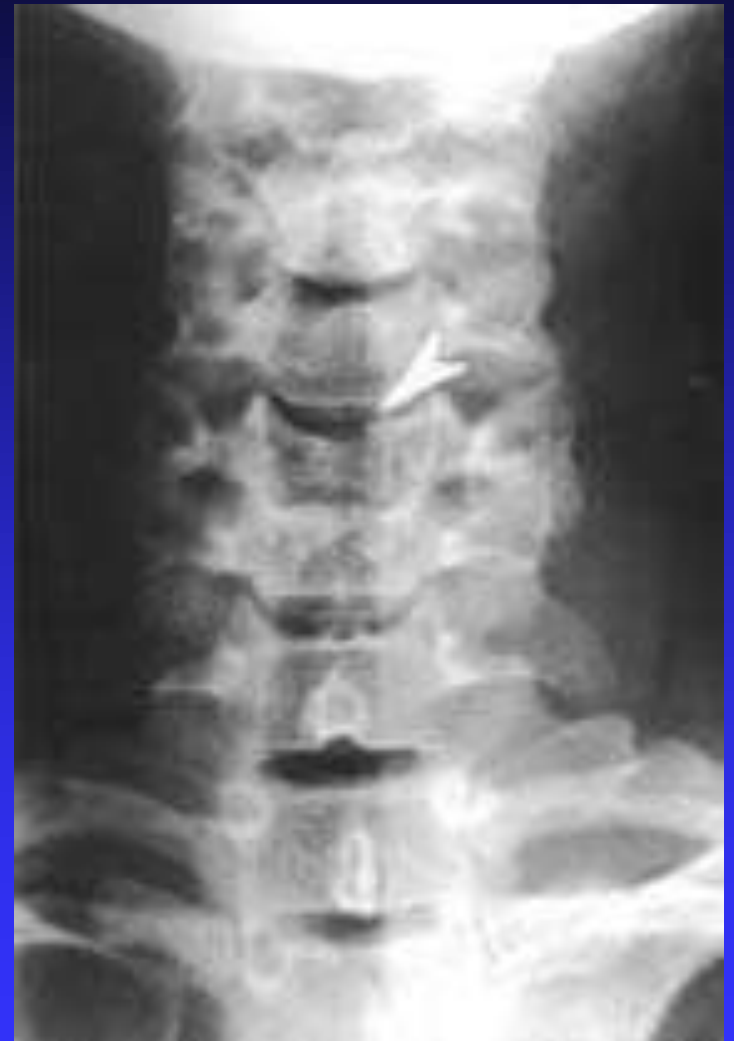
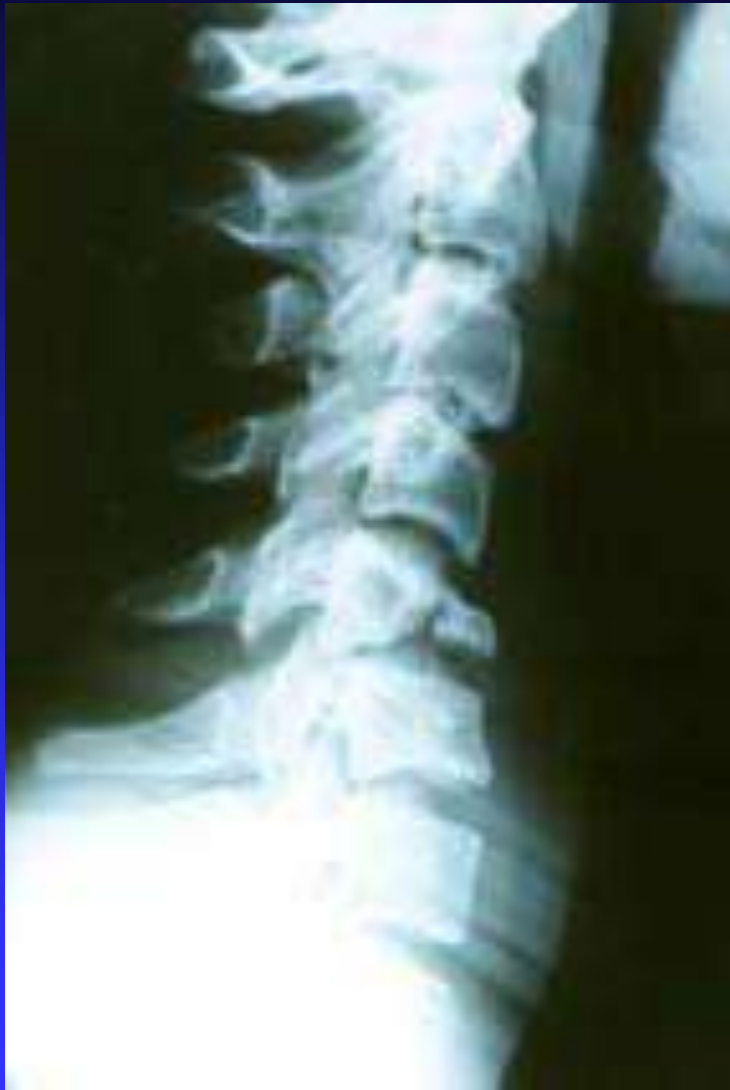
Treatment for Facet Dislocation

- Surgical reduction and spinal fusion

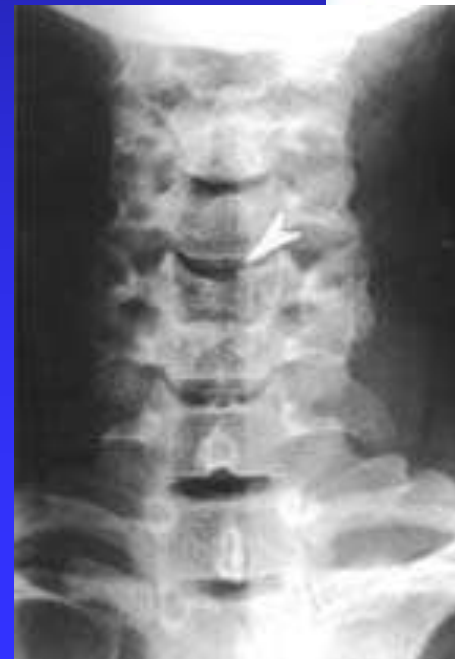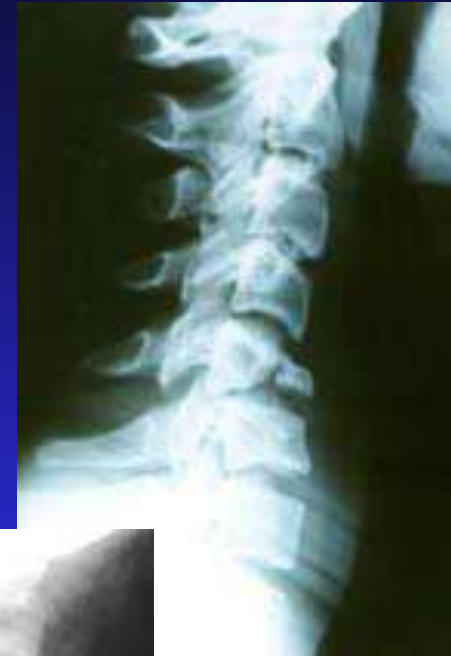Case





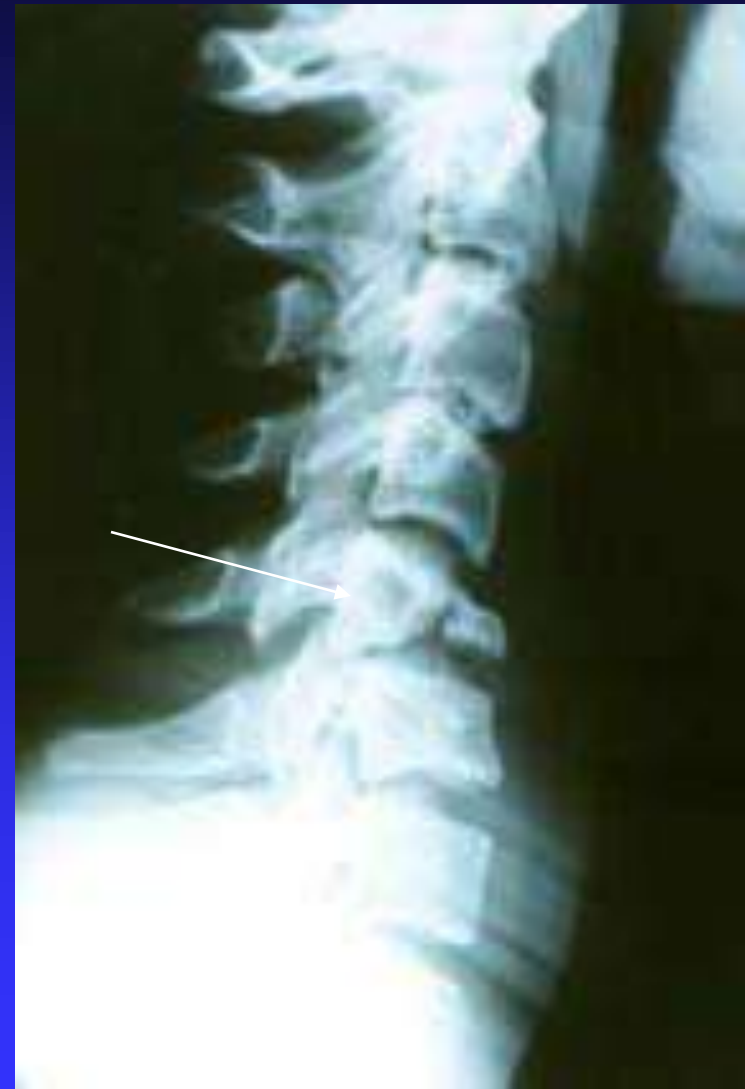Findings

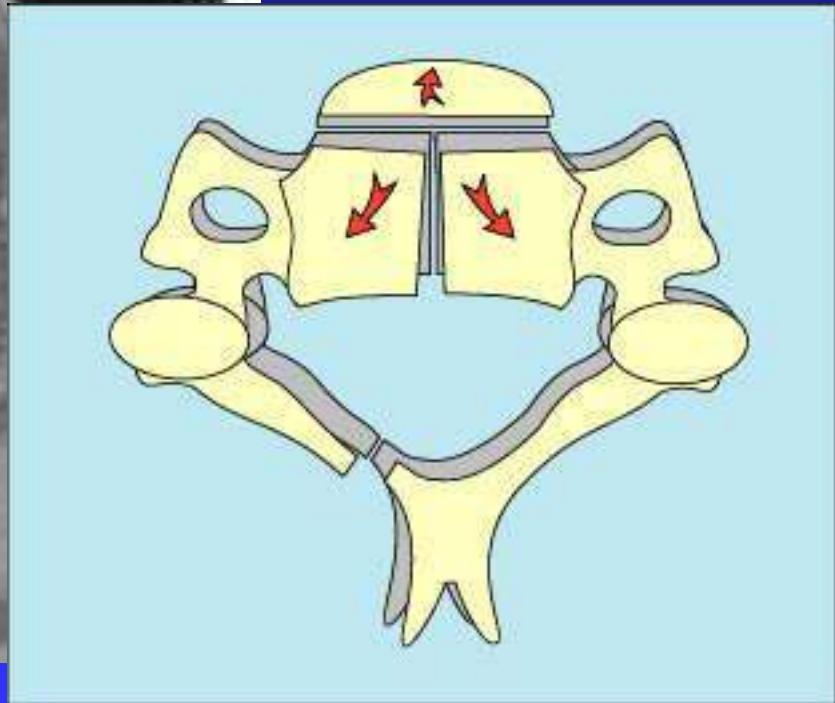
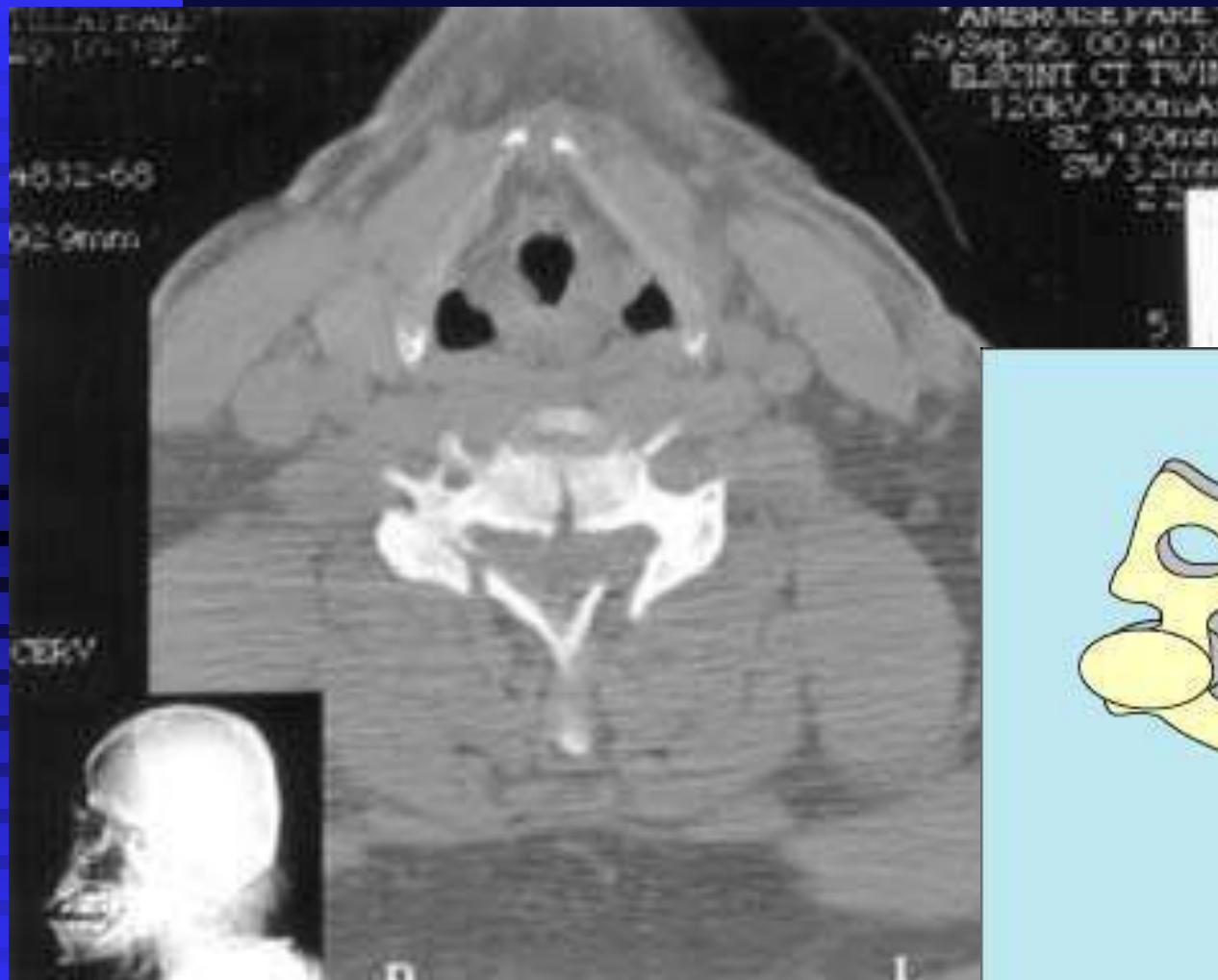
- Angulation of the cervical spine
- Vertical fracture & compression fracture of C5 body
- Mild perched C5 facet joint
- Degenerative changes



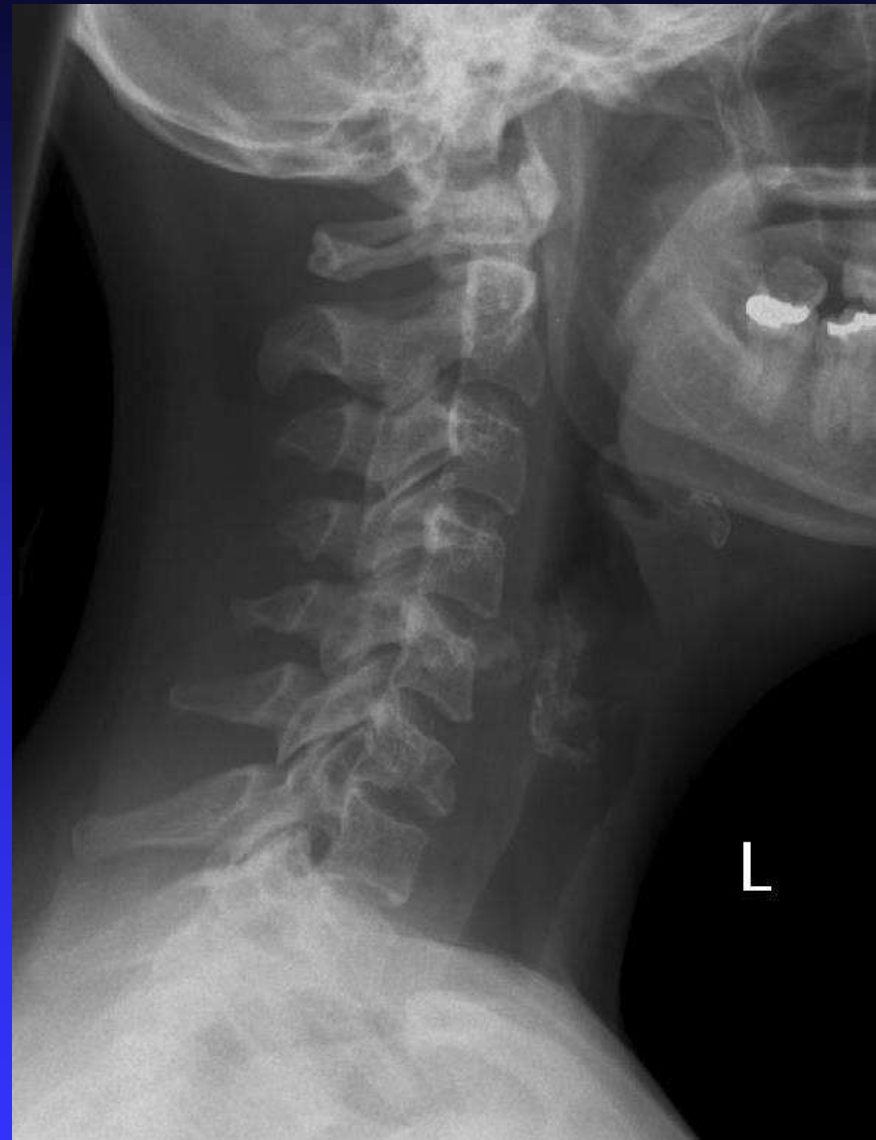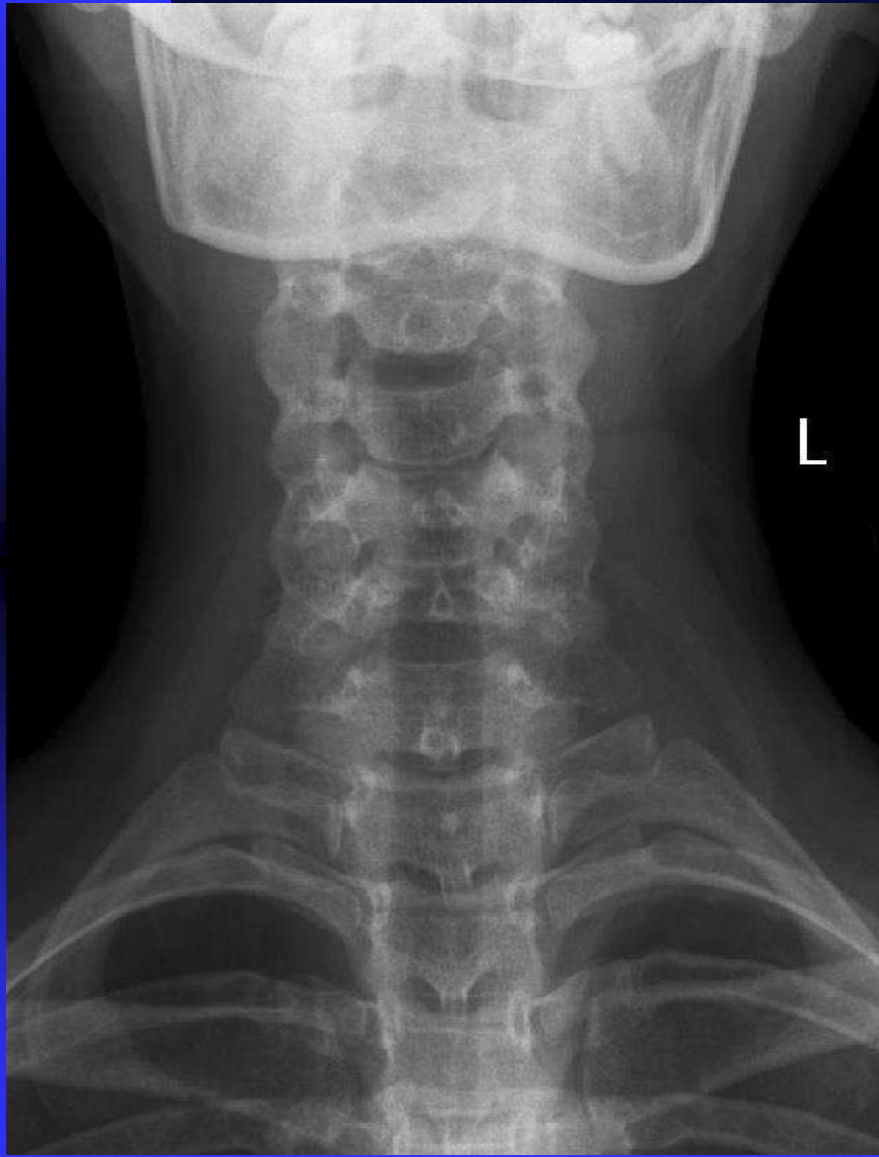Burst Fracture

- Widening of interpediculate distance (AP view)
- **Posterior displacement of the fracture fragment**
 - **Compromise of the spinal canal**



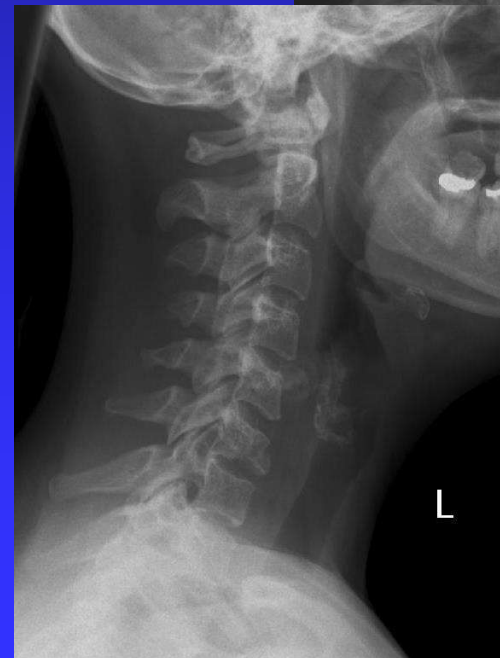
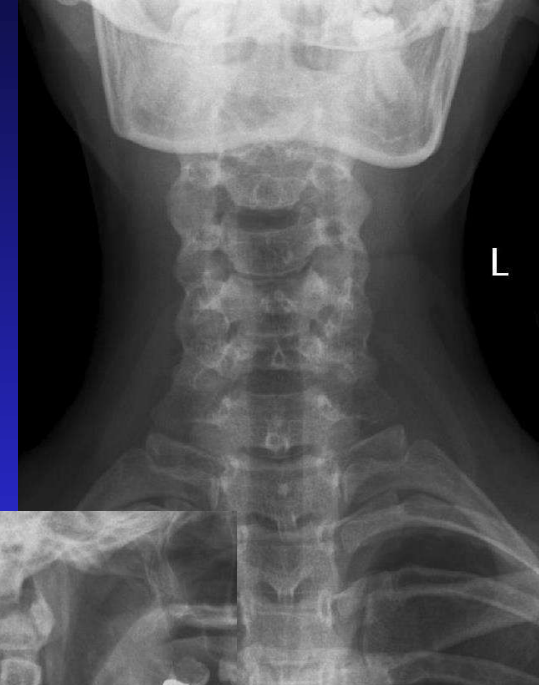
Case: Trauma



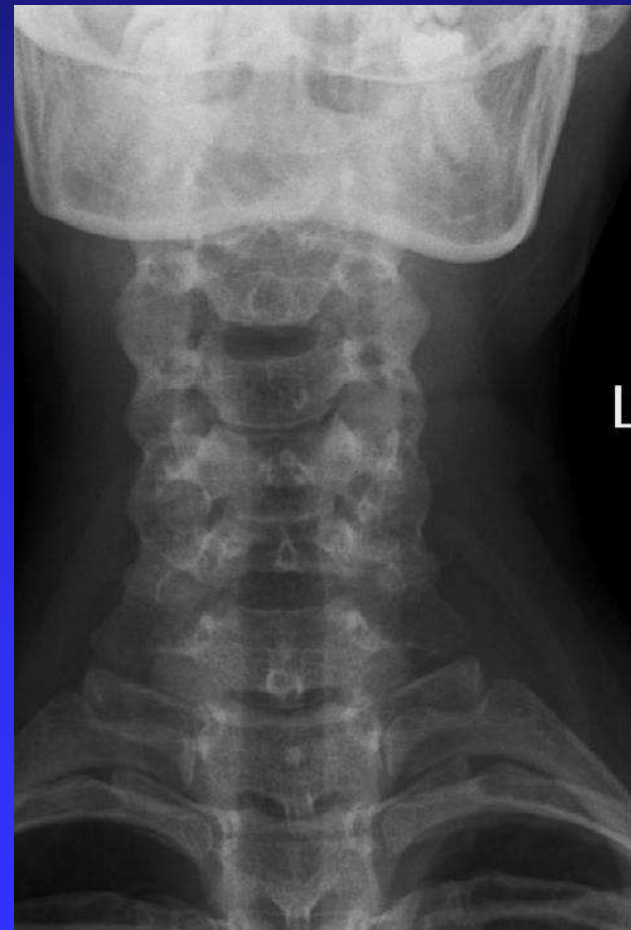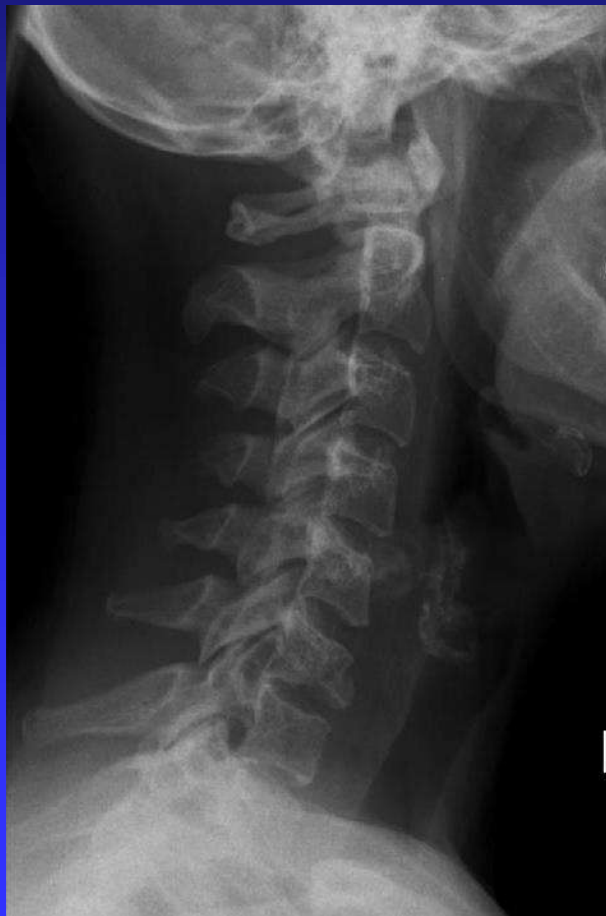Findings and Diagnosis

- Anterior head carriage & Postural alterations
- Uncovertebral arthrosis; Facet arthrosis
- Widened interspinous distance
- Teardrop fracture of anterior margin of the C6
- Compression fracture of superior endplate of C5



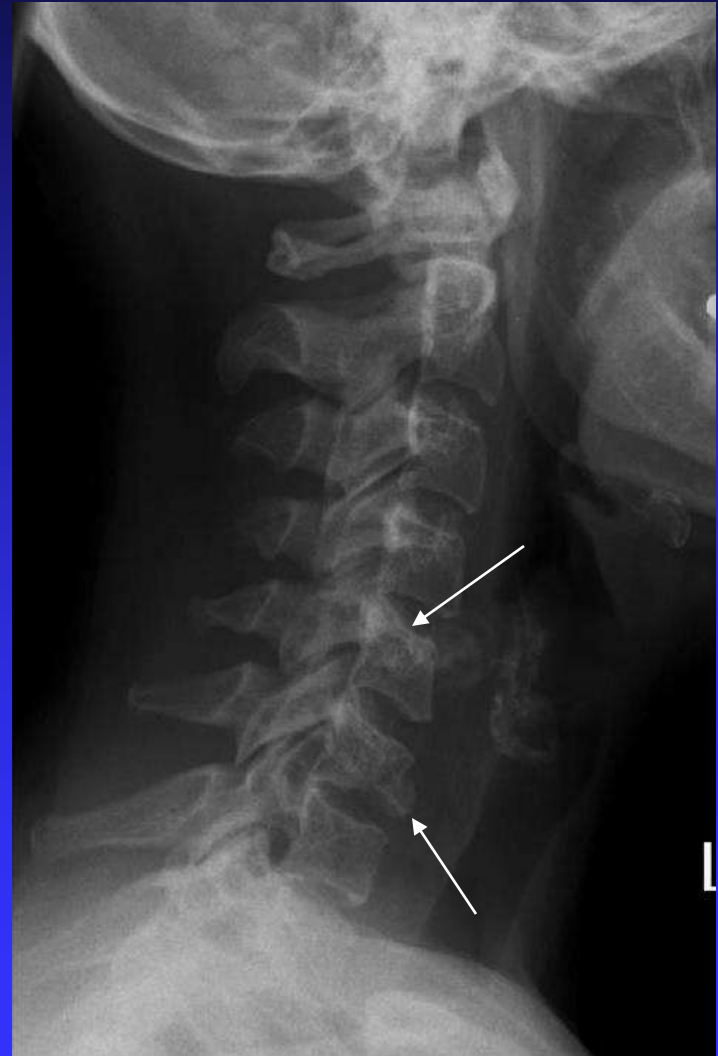Teardrop Fracture at C6

- Mechanism of Injury: Hyperflexion plus compressive force

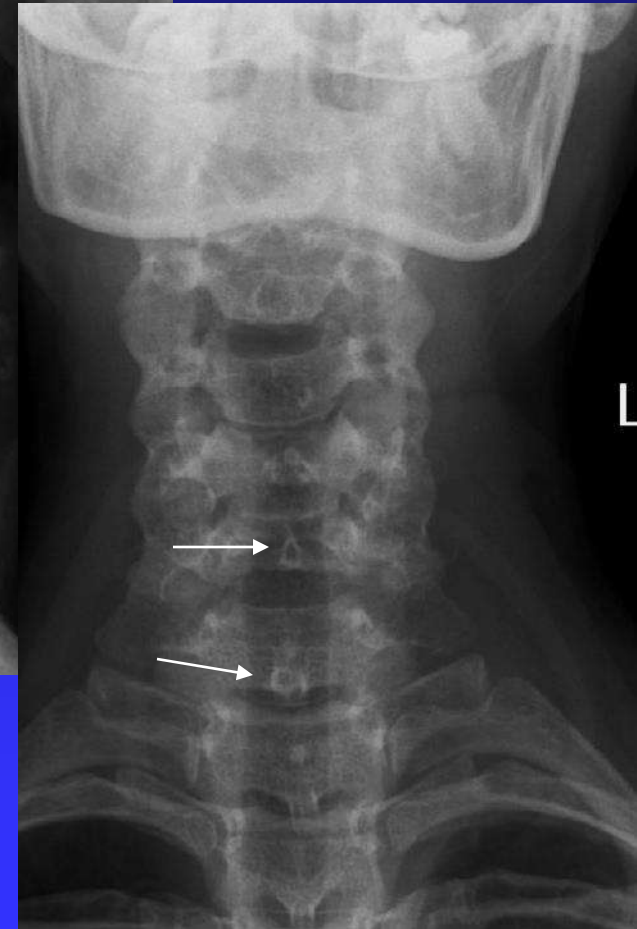
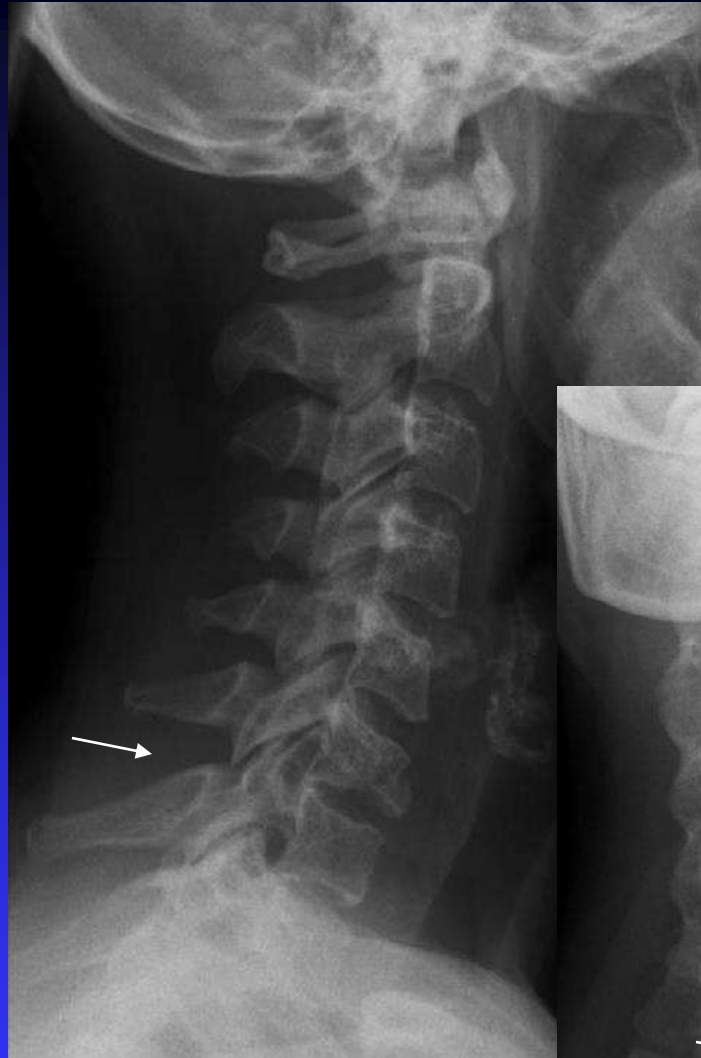

Hyperflexion Teardrop Fracture

- Triangular fracture fragment along the anteroinferior margin of C6; compression fracture at C5.



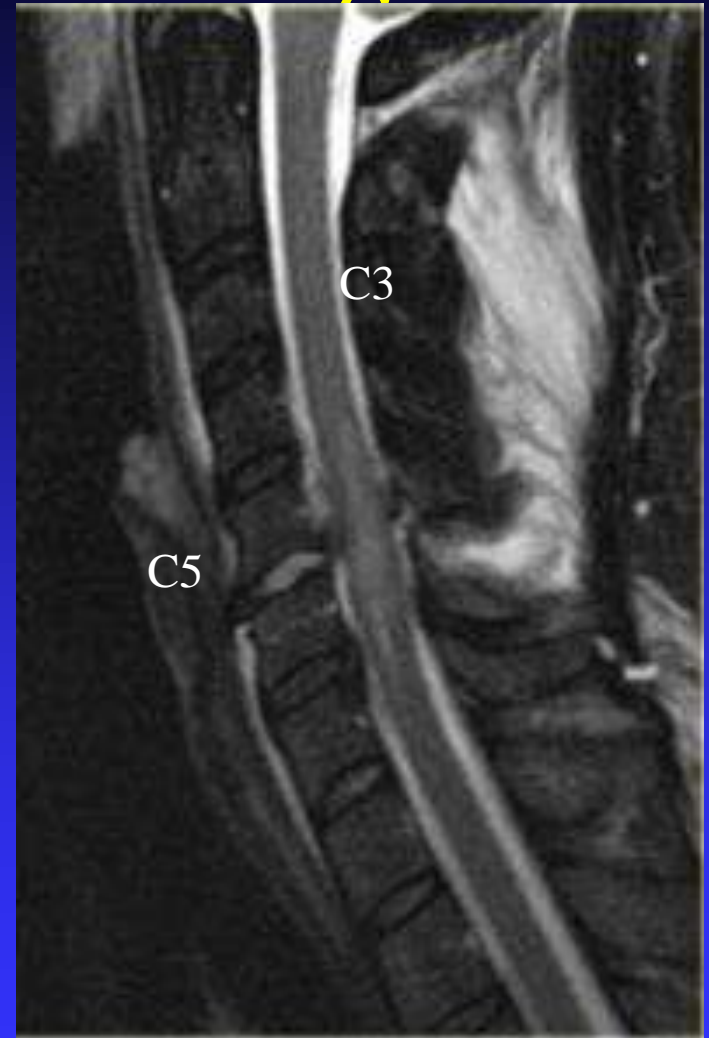- **Rupture of the interspinous ligaments**
 - Widened interlaminar and interspinous



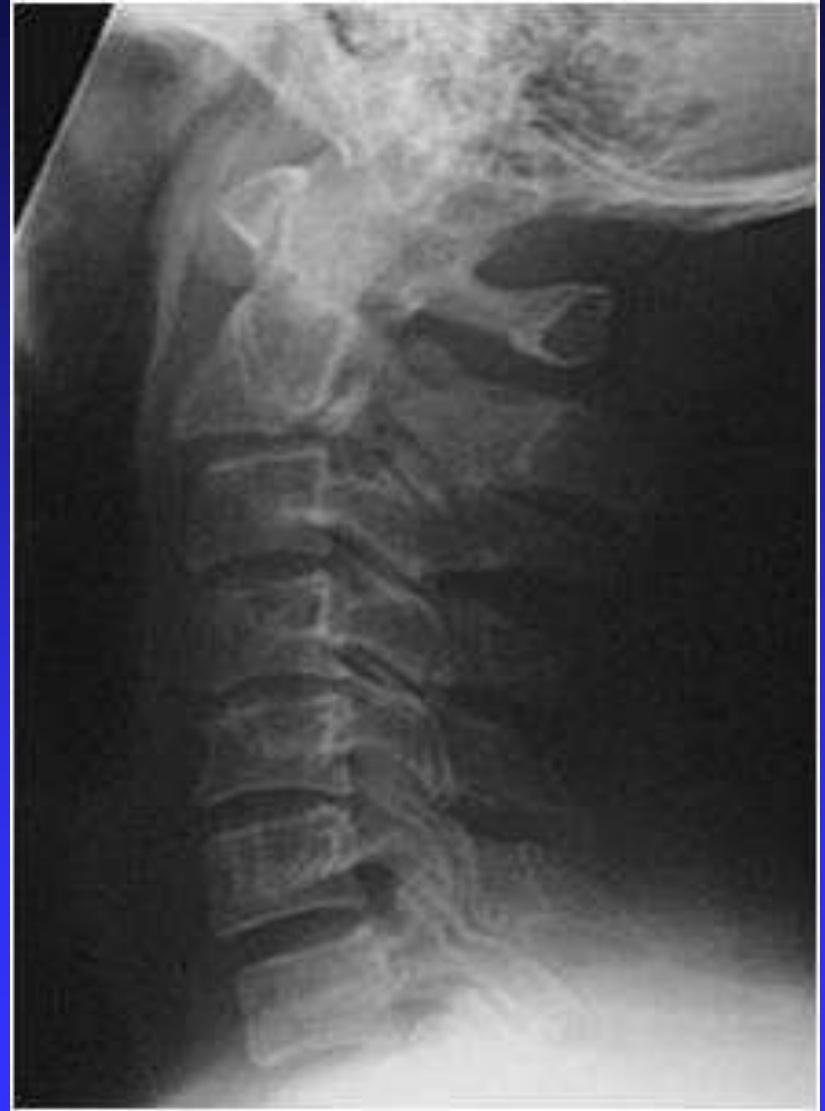Sagittal T2 Weighted Images

(Different Case of Hyperflexion Injury)

- C5-C6 level
 - Disruption of disc with increased signal within the disc (too bright)
- Increased signal within the posterior soft tissues and spinal cord due to edema and interspinous ligament disruption

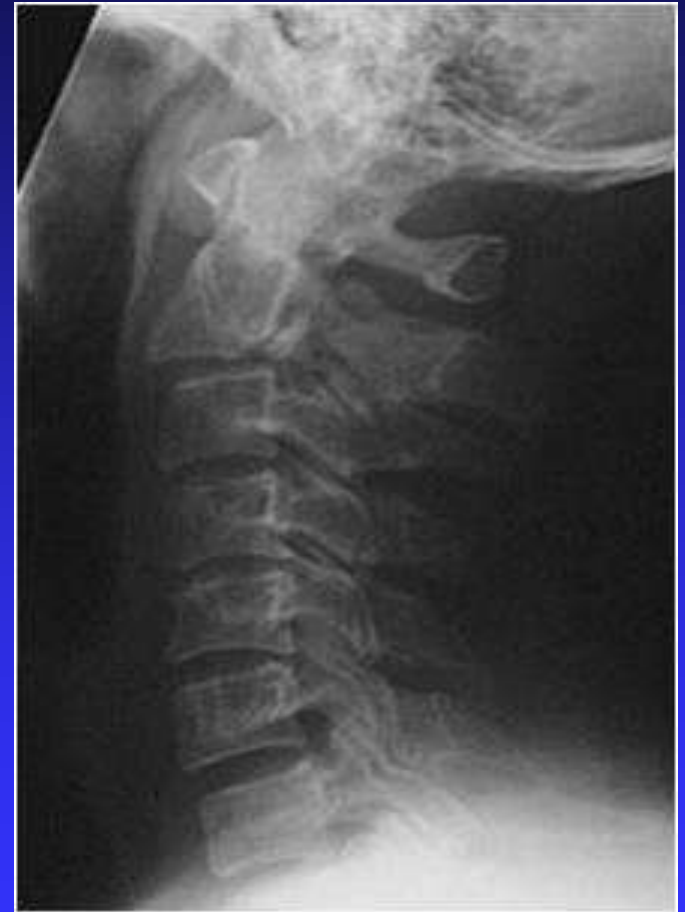

Case- Trauma

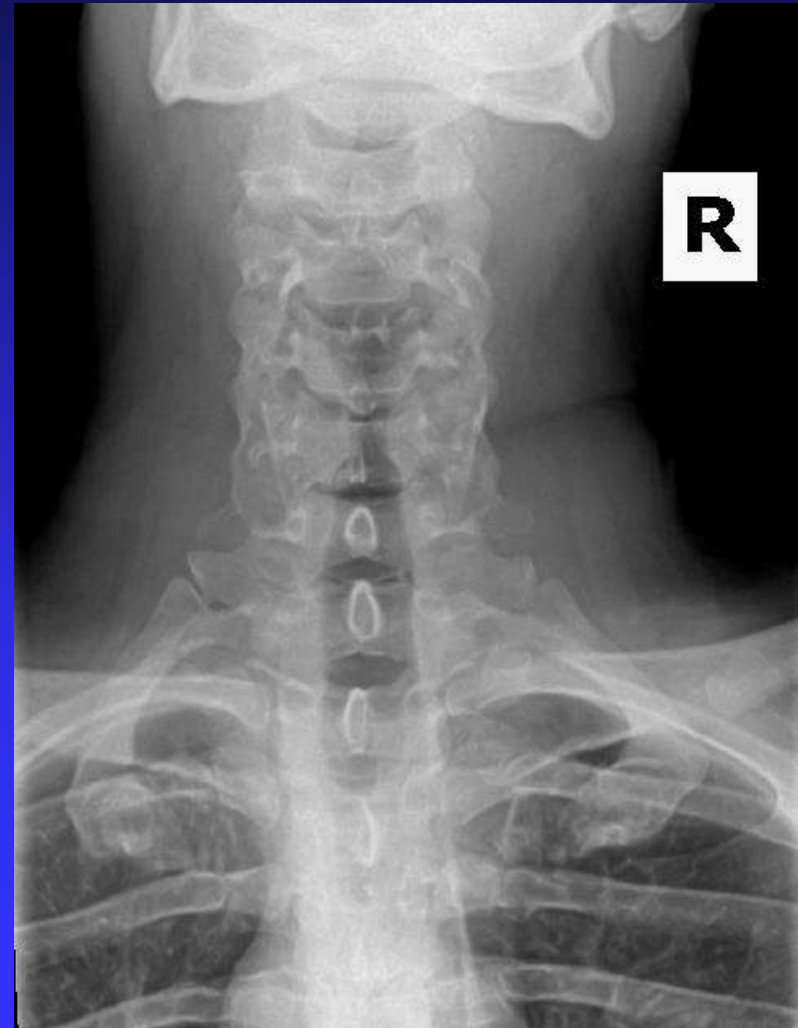
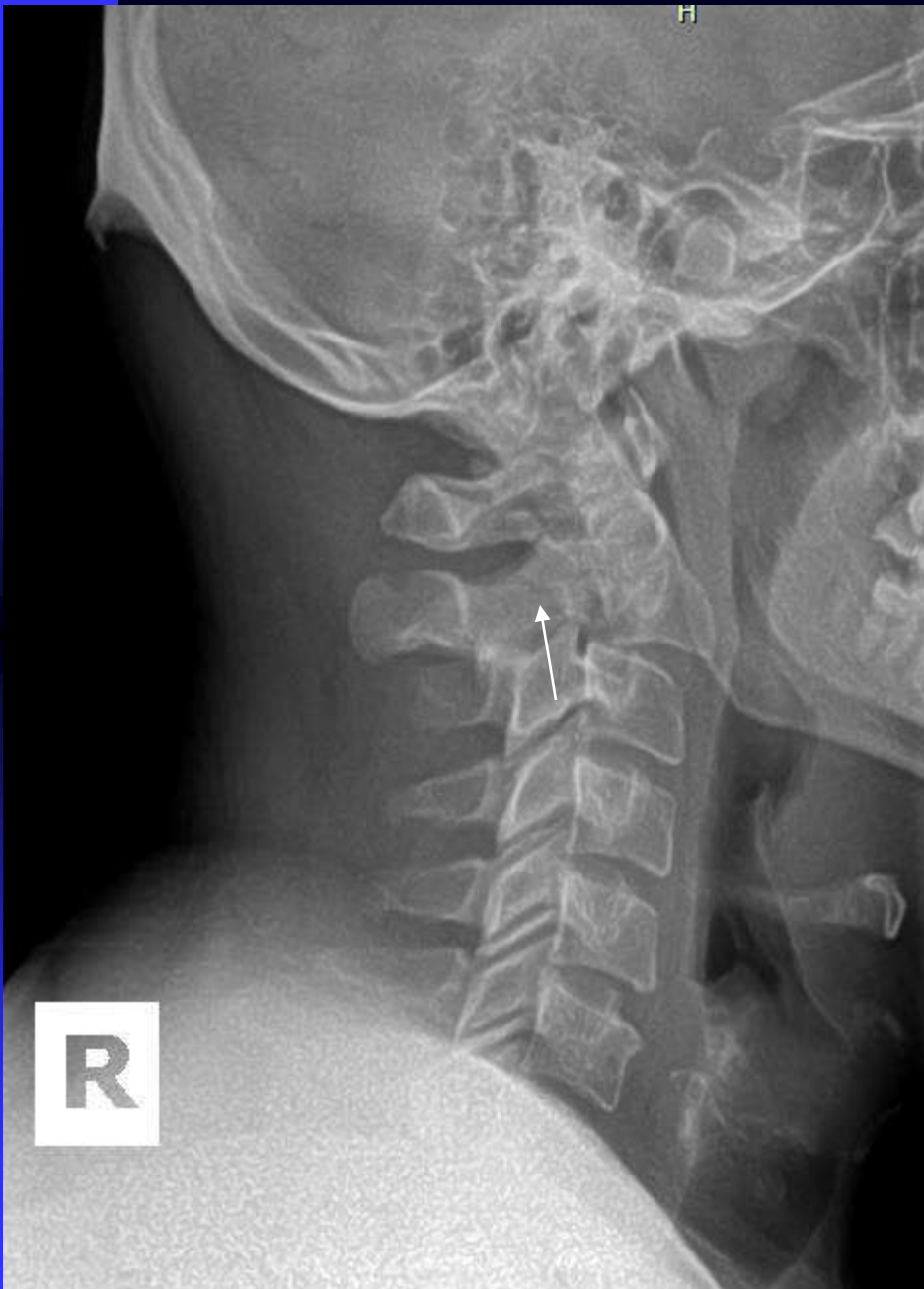
Findings

- Pedicle fracture of C2
- Facet dislocation & body displacement of C2
- Disruption of spinolaminar line, C1 & C2
- Osteopenia
- Degenerative disc disease & Facet arthrosis

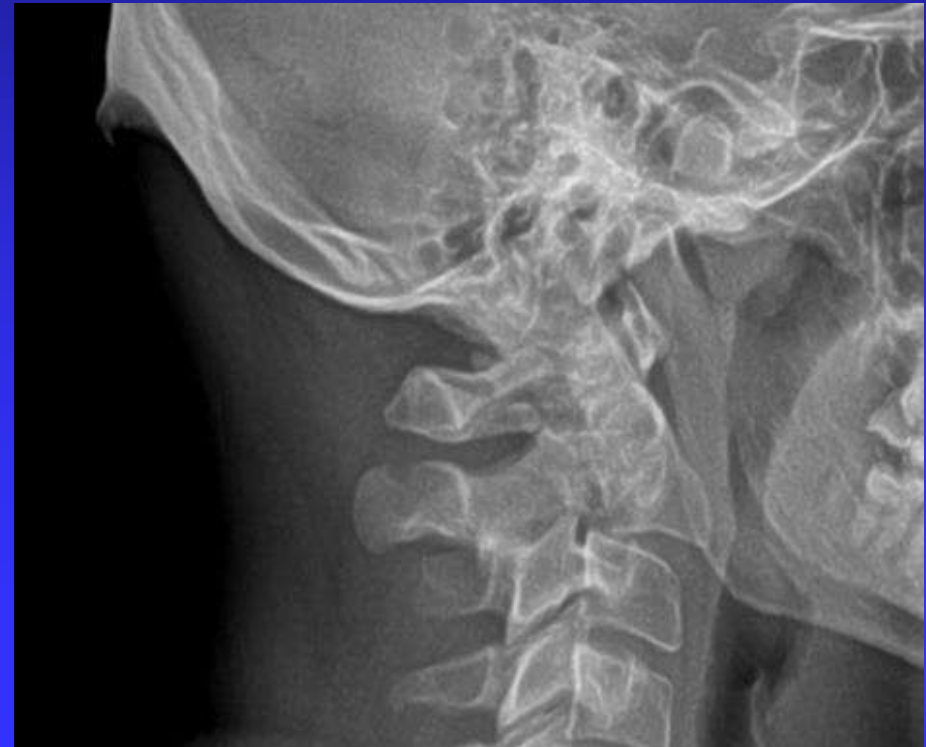

**ANOTHER PATIENT-
Skateboarder hit by a car;
Diagnosis missed at Urgent Care.**



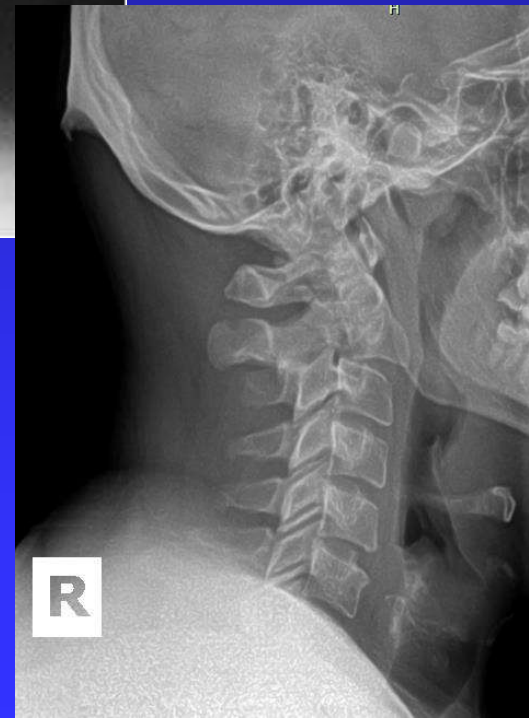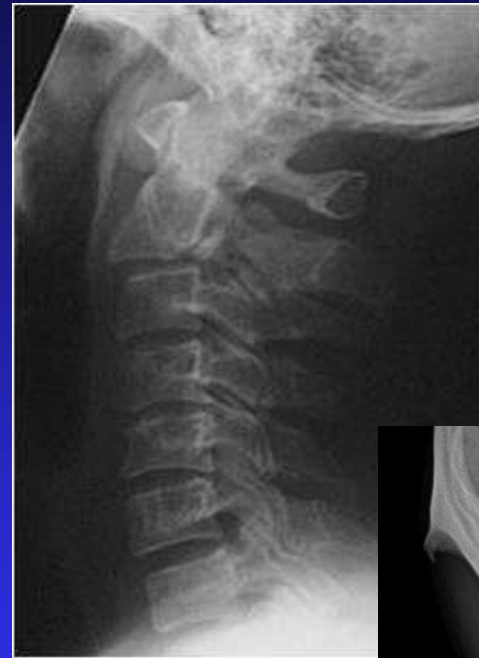Findings

- C2 appears to be in extension with the anterior, inferior portion of C2 consisting of anterolisthesis

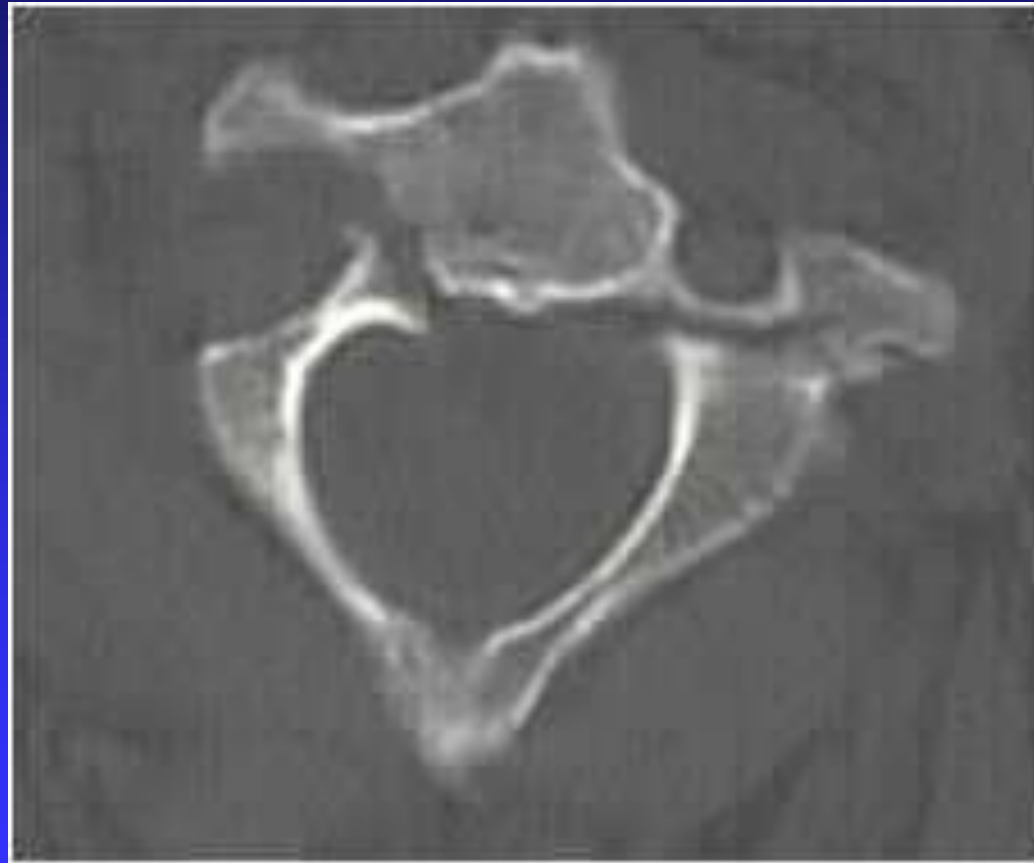


Hangman's Fracture

- Also known as Traumatic Spondylolisthesis of C2.
- Hyperextension and compression Injury



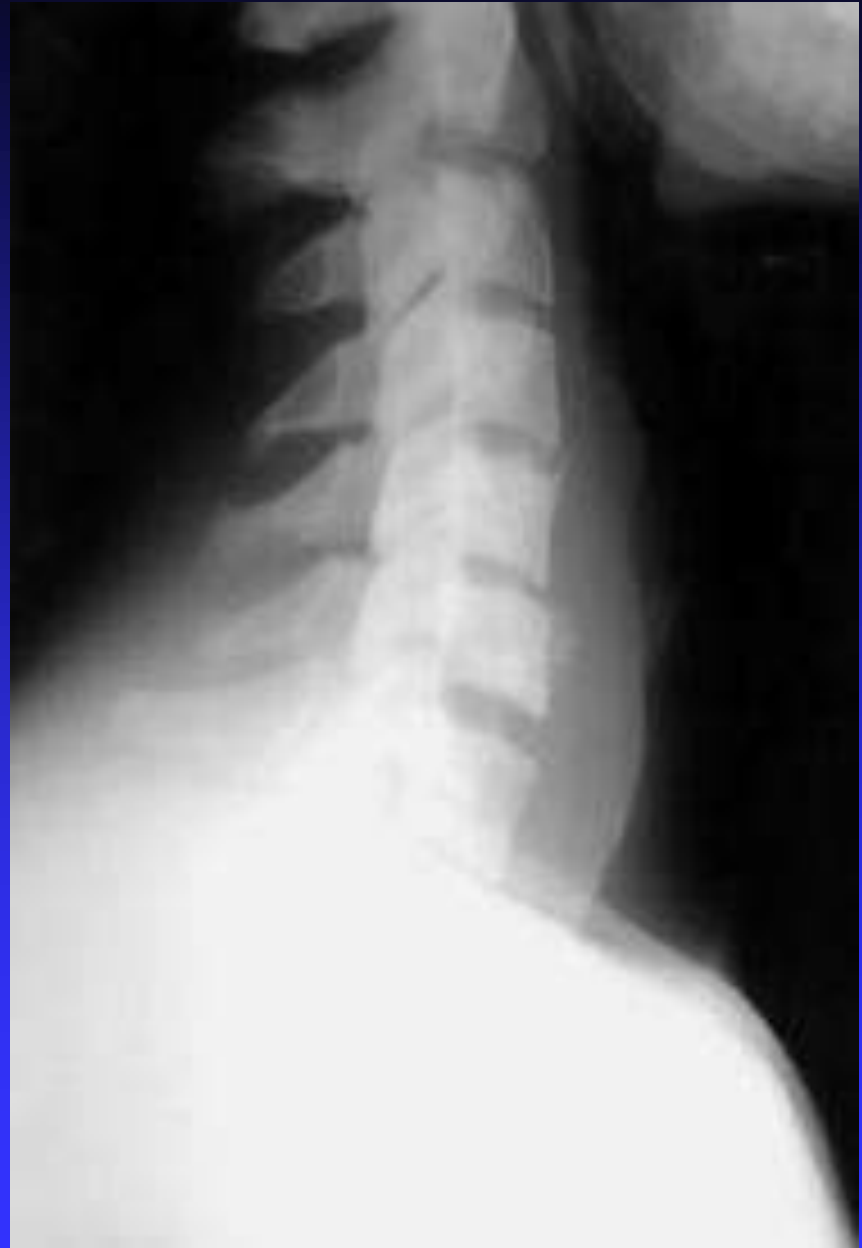Axial CT of Hangman's Fracture



Donated by Dr. Christopher Watkins, DACBR

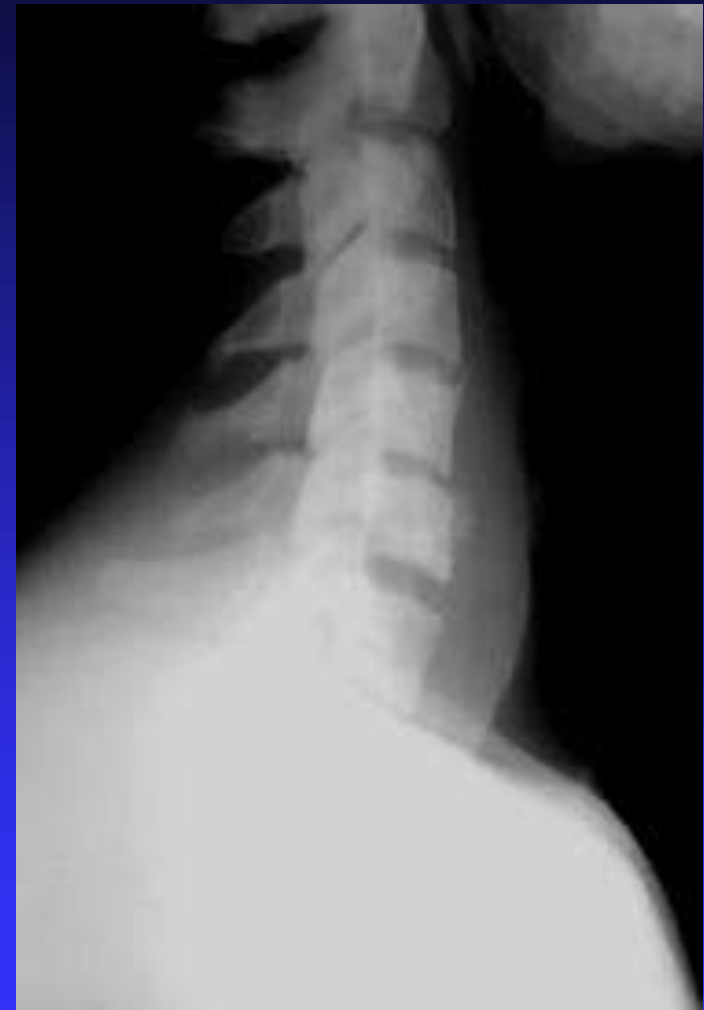Case

Patient had trauma, whiplash mechanism of injury. The neutral lateral view appears normal.



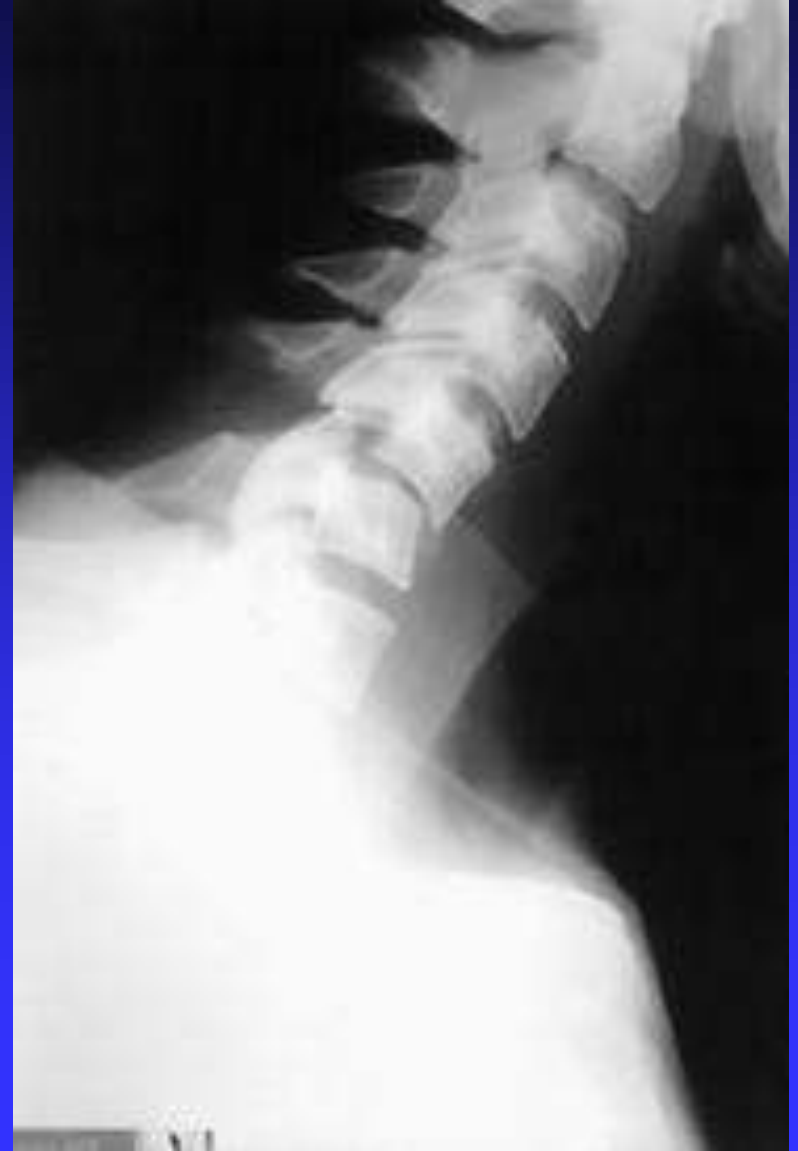Findings

- Straightening of the cervical lordosis
- Mild facet arthrosis of C4-C5 and C5-C6
- Mild degenerative disc disease
- Mild soft tissue swelling
- **What other views are necessary due to history and clinical findings?**

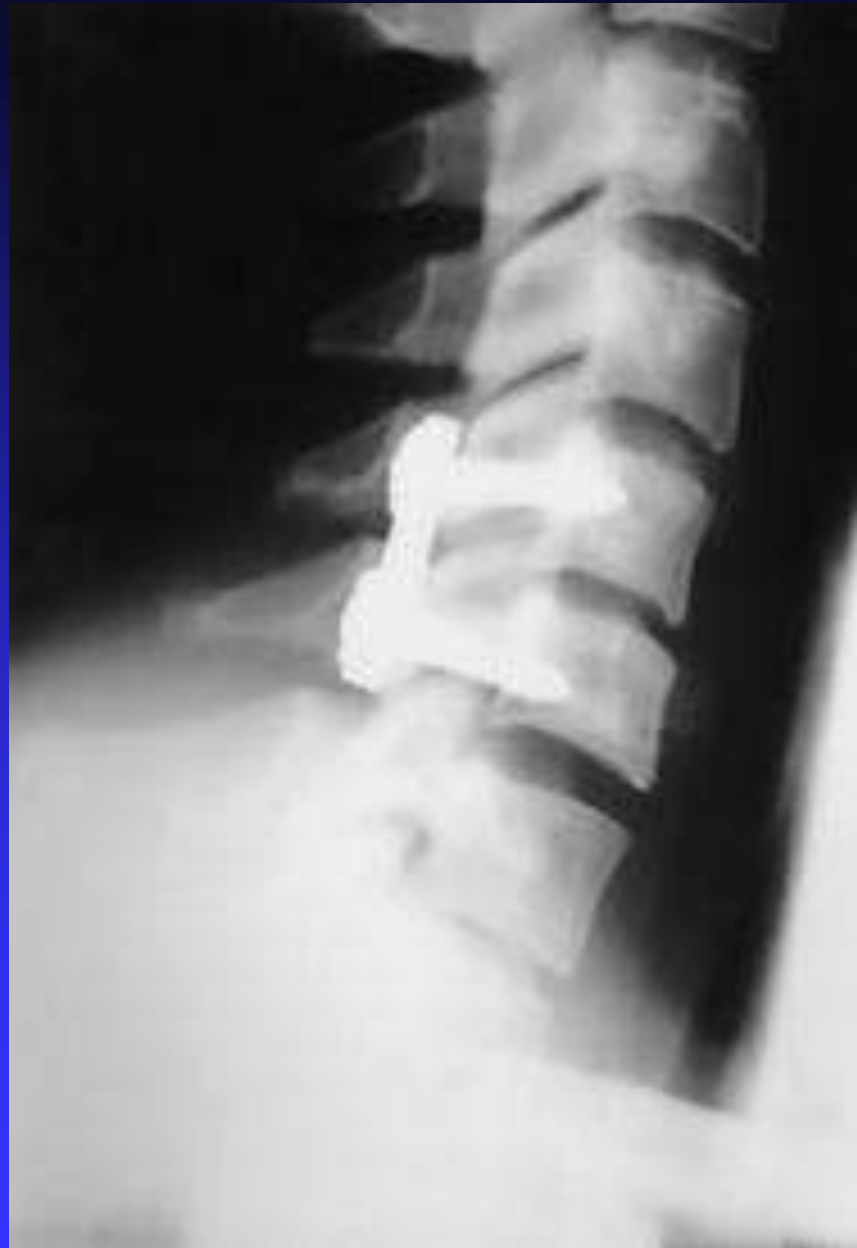

Flexed Lateral View

Facet joint at C5-
C6 dislocates
with flexion.



Follow-up

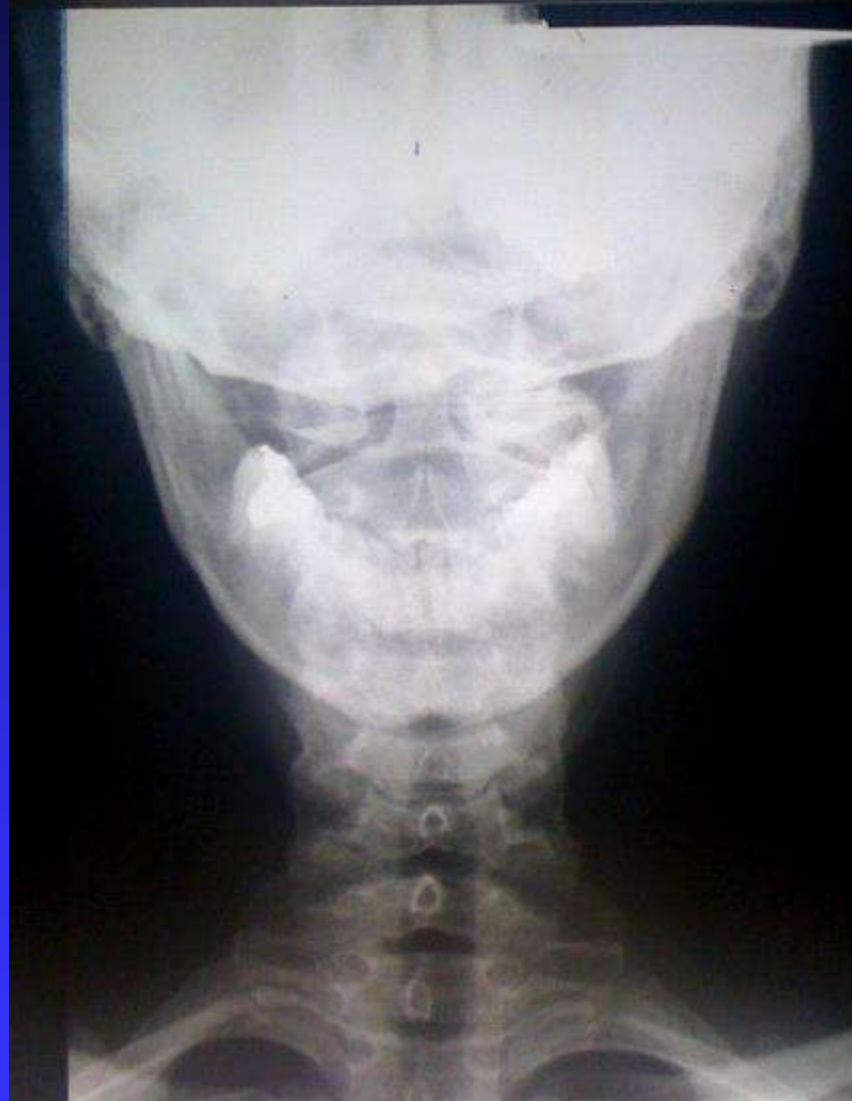

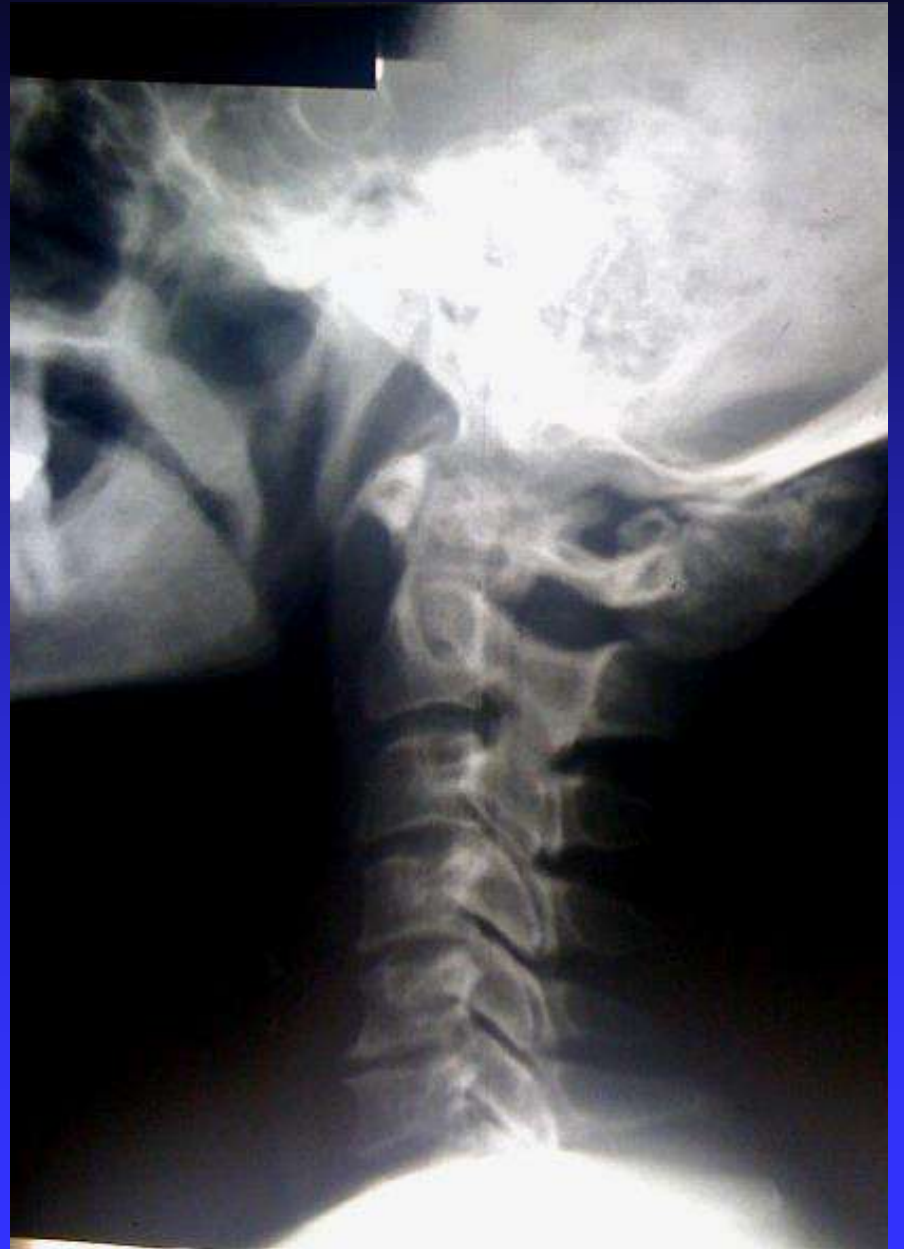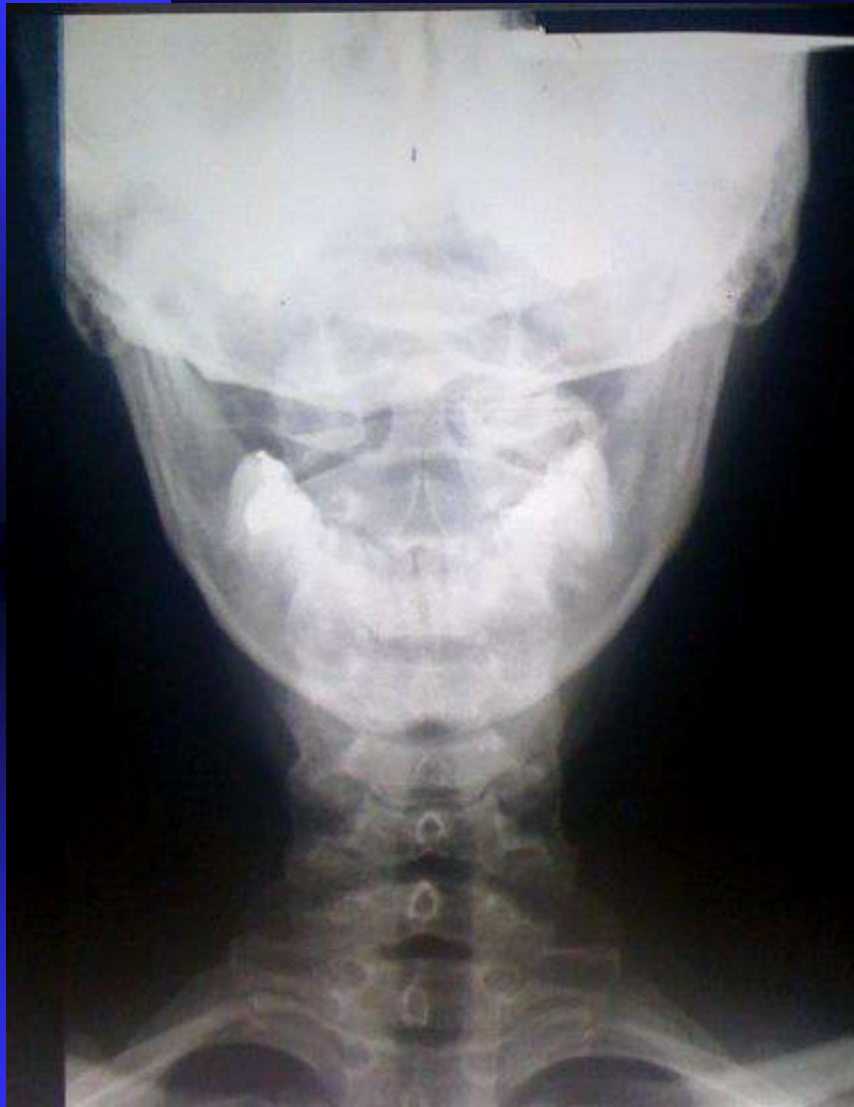Treatment

- Surgical reduction and fusion is required to eliminate re-dislocation and injuring the spinal cord.

Case

Patient was experiencing fullness and tension at the base of the skull





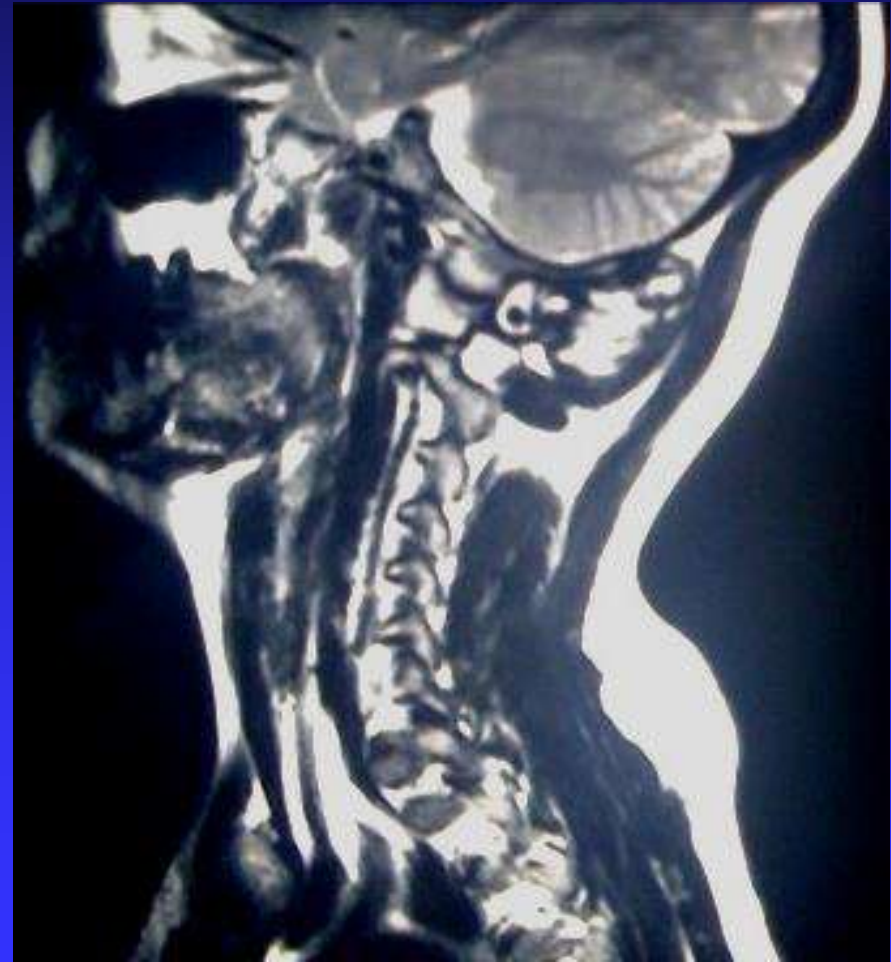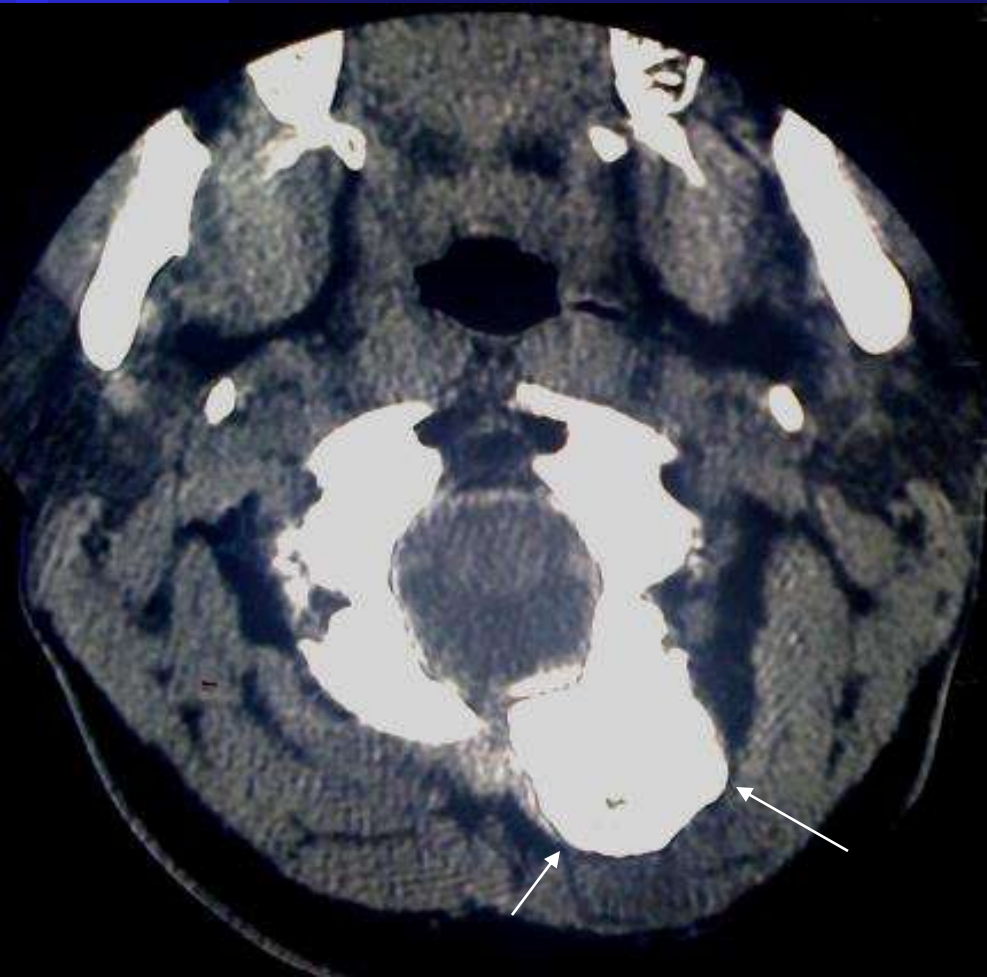Findings

- Osseous mass either from C1 or occiput
- Differential: Osteoblastoma, or possibly bone cyst
- Degenerative disc disease at C3-C4, C4-C5 and C5-C6
- Postural alterations.

Osteoblastoma

- Base of the left occiput
- Most common benign, posterior tumor of the spine.
- Referral: Neurosurgeon for resection

CT & MR of Osteoblastoma



References

- Resnick, D. *Diagnosis of Bone and Joint Disorders*. 2002, 4th edition; 2950-2979.
- Yochum T and Rowe L. *Essentials of Skeletal Radiology*. 1996, 2nd edition; 207-8; 670-693.
- Stiell I, et al. The Canadian C-Spine Rule versus the NEXUS Low-Risk Criteria in Patients with Trauma. *N Engl J Med*; Dec 2003, 349 (26), 2510-8.
- Eyre, Andrew. Overview and Comparison of NEXUS and Canadian C-Spine Rule. *Am J Clinical Med*, 2006; 3 (4), 12-15.
- Dvorak J, et al. Biomechanics of Craniocervical Region: The Alar and Transverse Ligaments. *J of Orthopedic Res*, February 2005; 6 (3), 452-61.
- Derrick LJ and Chesworth BM. Post-Motor Vehicle Accident Alar Ligament Laxity. *J of Orthopedic and Sports Physical Therapy*, July 1992; 16 (1), 6-11.
- Bergmann & Peterson. *Chiropractic Technique*, 2nd edition; 202.

www.jprad.com




700 East Redlands Blvd, Redlands CA. 92373 909.353.9348 jpedley299@yahoo.com

www.jprad.com

- **Detailed radiology reports with recommendations & clinical information**
- **X-ray & MRI consultation**



The End



Thanks for taking CE Seminars with Back To Chiropractic. 😊
I hope you enjoyed the course. Please feel free to provide feedback.

Check out: Back To Chiropractic Resources

Free Materials: Notes & Forms hundreds of files ~ posters, newsletters & more

Services & Listings People helping people for free

Marcus Strutz DC

Back To Chiropractic CE Seminars

marcusstrutzdc@gmail.com

707.972.0047

